Il futuribile

Esperienze da condividere

Esperienza del Fisico Medico nella Tomosintesi inserita nel programma di screening mammografico

F.Cavagnetto

IRCSS A.O.U.San Martino – IST - Genova

Finalborgo

18 Maggio 2016

Lo screening mammografico in Liguria

- **1997**: In applicazione del PSN 1994-96, il Consiglio Regionale della Liguria approva le "Linee guida per la prevenzione e cura delle malattie oncologiche" (Del. n. 57, 16.09.97)
- **1998**: Commissione Oncologica Regionale:
- Sottogruppo: ***SCREENING MAMMOGRAFICO:***
  - Rappresentanza dei 5 Poli Oncologici regionali
  - Figure professionali specialistiche
    - Radiologo
    - **Fisico Sanitario**
    - Epidemiologo
    - Anatomo-patologo
  - Rappresentanza dell'utenza (Centro per i diritti del malato)

Lo screening mammografico in Liguria

- **1999** : Giunta Regionale n.1346 del 12/11/1999
  - Finanziamento
- **Luglio 2000 – Giugno 2002**:
  - Progetto di fattibilità: ASL 3 – Genovese (Ponente)
- Giunta Regionale n. 1646 (24/12/2001)
  - Programma di prevenzione per le più frequenti patologie oncologiche:
- "**Estensione dello screening mammo-grafico su tutto il territorio ligure**"

Lo screening mammografico in Liguria

Programma di garanzia della qualità per gli aspetti Fisici e Tecnici

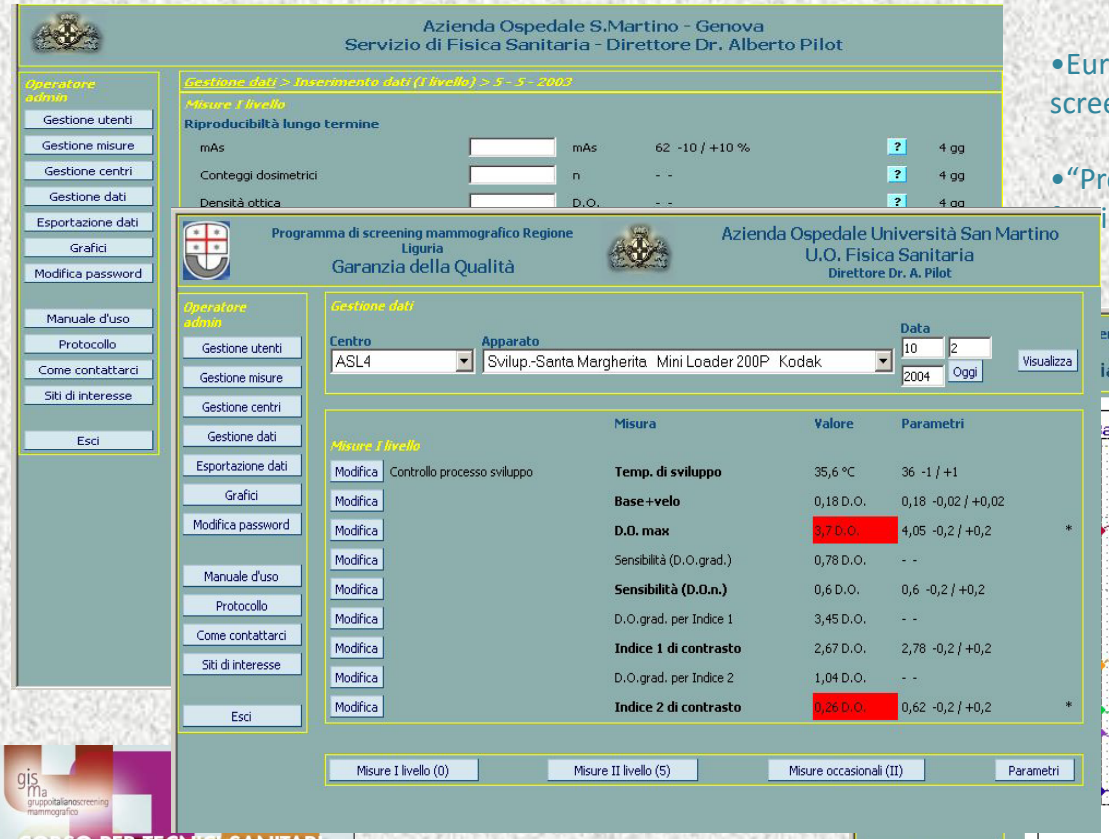

- European giudelines for quality assurance in mammography screening" EUR (2001) *Third edition*
- "Protocollo italiano per il controllo di Qualità degli aspetti fisici e tecnici in mammografia" *Report AIFM n°1 - 2004*

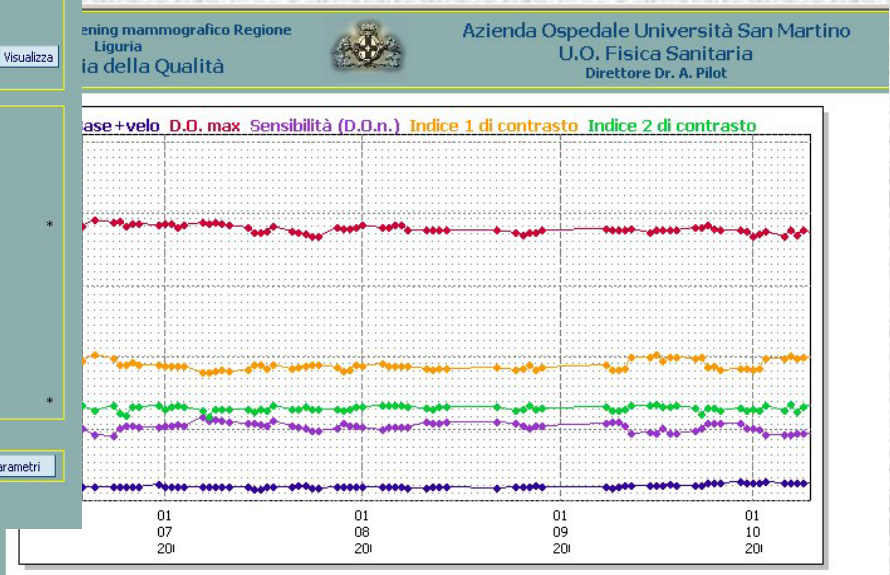

Lo screening mammografico in Liguria

Programma di garanzia della qualità per gli aspetti Fisici e Tecnici

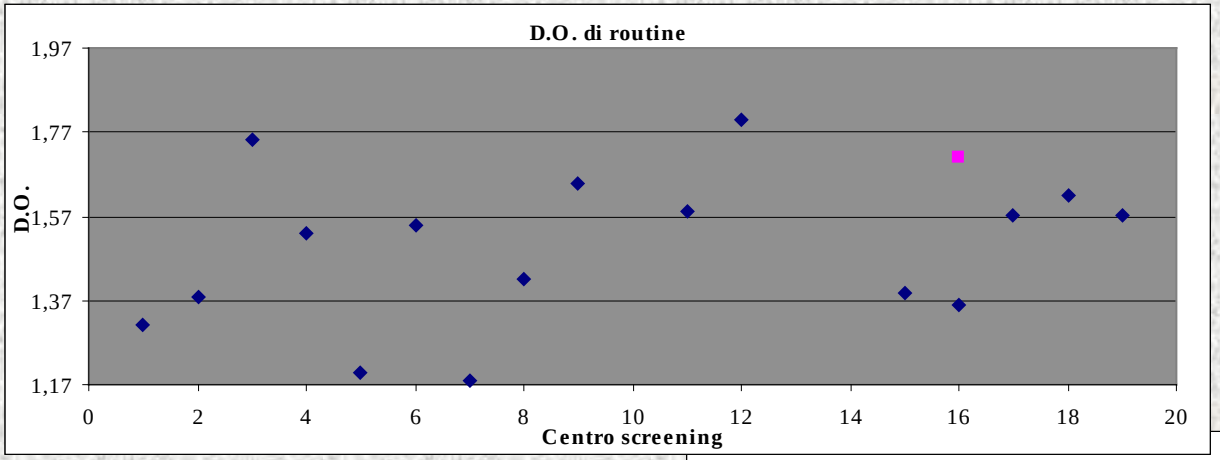

Interconfronti tra i vari centri con lo scopo di ottimizzare e uniformare le prestazioni

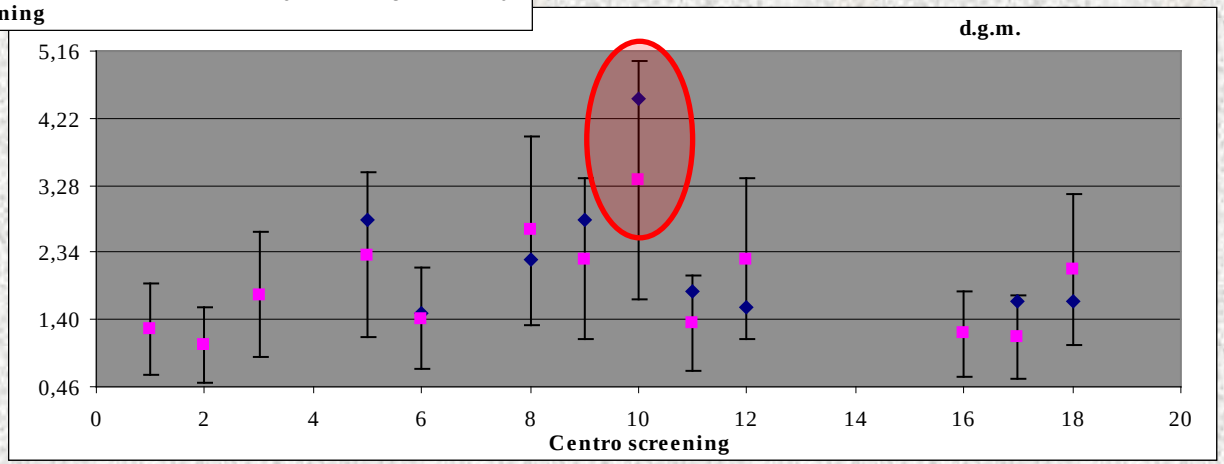

Lo screening mammografico in Liguria

- Il programma di **Screening Mammografico della ASL3 Genovese**, coordinato dalla **Dott.ssa I.Valle** e dalla **Dott.ssa N.Gandolfo** ha previsto diversi **GDL** tra cui **GDL1:**

Controlli di qualità-Aspetti Fisici e Tecnici

Coordinato dalla **Dott.ssa N.Canevarollo – Dott. F.Bisi**

- Protocollo dei Controlli di Qualità per Apparecchiature Mammografiche Digitali Dirette (DD) e Indirette (CR)" revisione 1.1 del 15/11/2013 –
  - allegato poi al documento 11/2015 della **Rete HTA della Regione Liguria** (Ing.G.Paoli et al.) "Criteri per l'appropriatezza allocativa di alcune apparecchiature - Vol.5 Mammografi e VABB "
- Lavoro di **Intercalibrazione Strumentazione Mammografica**
- «Intercomparison on the assessment of CNR in digital mammography, measurement tests of the new index SDNR defined in the Supplement of the European Guidelines» **VIII Congresso Nazionale AIFM di Torino 2014** E.M.L. Vaccara, M.Piergentili, F.Bisi, N.Canevarollo, F.Cavagnetto, O.Ferrando, F.Foppiano, F.Pupillo, D.Rembado, A.Rivolta, R.Rosasco, G.Taccini, E.Zucchi

Lo screening mammografico in Liguria

- 02/2016 **IX Congresso Nazionale AIFM** di Perugia i seguenti lavori :
  - "Average Glandular Dose (AGD) in Mammography: reliability of recorded data in order to comply to Council Directive 59/2013/EURATOM
  - F.Bisi,N.Canevarollo, F.Cavagnetto, F.Foppiano, M.Piergentili, A.Rivolta,R.Rosasco, A.Rivolta, E.Zucchi
  - "A proposal of Mammography QC-Related Indicator for HTA Evaluation"
  - M.Piergentili, F.Bisi, F.Cavagnetto, N.Canevarollo, D.Rembado, A.Rivolta, R.Rosasco, E.M.L.Vaccara, E.Zucchi, R.Rebagliati, F.Foppiano
- **Gisma 2016** verrà presentato il lavoro:
  - "Verifica della stabilità di un indice di obsolescenza delle apparecchiature mammografiche digitali dirette (DD) al variare dei parametri di esposizione clinici"
  - M.Piergentili, F.Bisi, N.Canevarollo, F.Foppiano, D.Rembado, A.Rivolta, R.Rosasco, E.M.L.Vaccara, E.Zucchi

La Tomosintesi in Liguria

- **2009**: installazione Tomosintesi - IST – Genova
  - Hologic Selenia dimensions
- **Problematiche dosimetriche?**

Accoppiata Anodo-filtro: **W/Al 0,7mm** **(sottostimato)**

$$\mathbf{DGM} = AGD = ESAK \cdot \mathbf{g} \cdot \mathbf{c} \cdot \mathbf{s} \cdot T$$

Estimation of mean glandular dose for breast tomosynthesis: factors for use with the UK, European and IAEA breast dosimetry protocols

2011

D R Dance[1,2], K C Young[1,2] and R E van Engen[3]

[1]NCCPM, Medical Physics Department, Royal Surrey County Hospital, Guildford GU2 7XX, UK
[2]Dept. of Physics, University of Surrey, Guildford GU2 7XH, UK
[3]National Training and Expert Centre for Breast Cancer Screening (LRCB), Radboud University Nijmegen Medical Centre P.O. Box 6873, 6532 SZ Nijmegen, The Netherlands

La Tomosintesi in Liguria

Problematiche dosimetriche

Principio di giustificazione

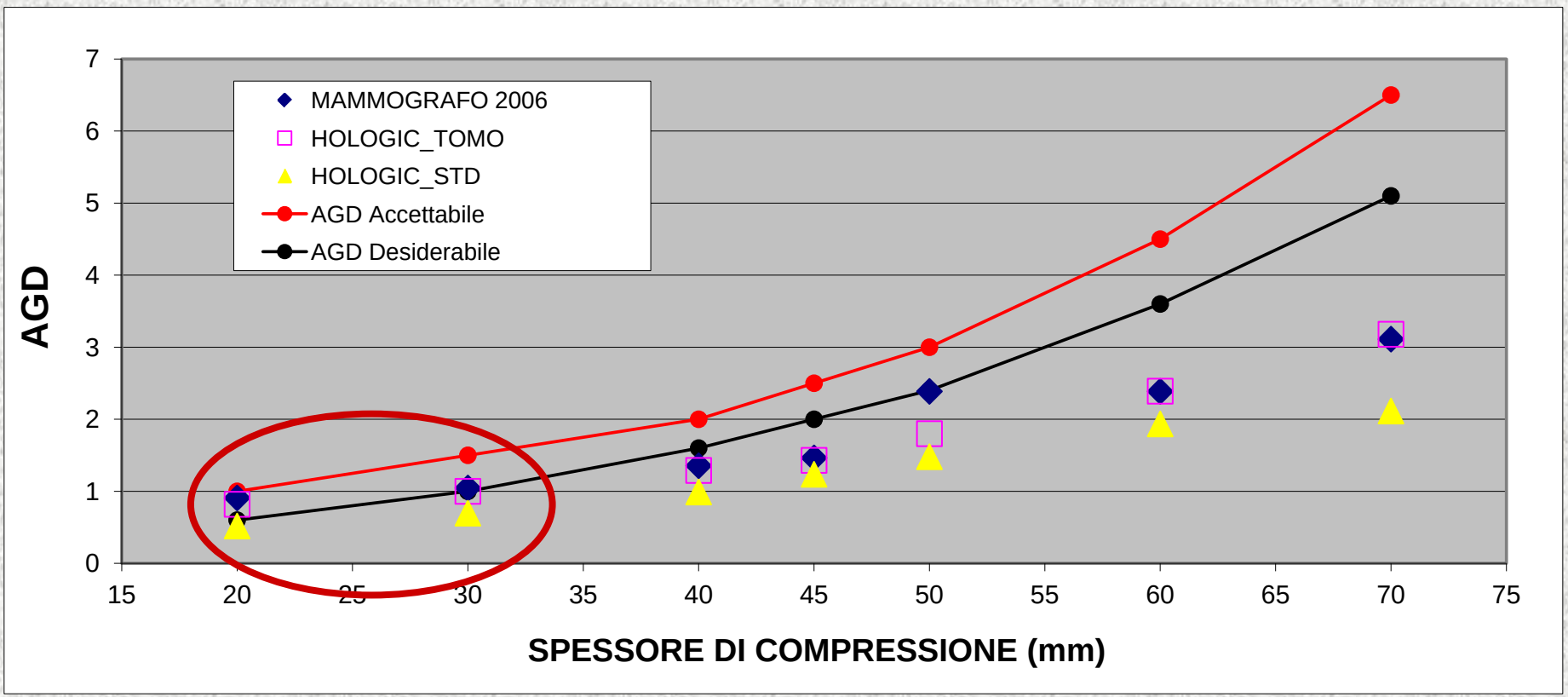

La Tomosintesi in Liguria

Problematiche dosimetriche

Principio di giustificazione

COMBO

Studi mirati

Studio multicentrico:
Hologic 2011

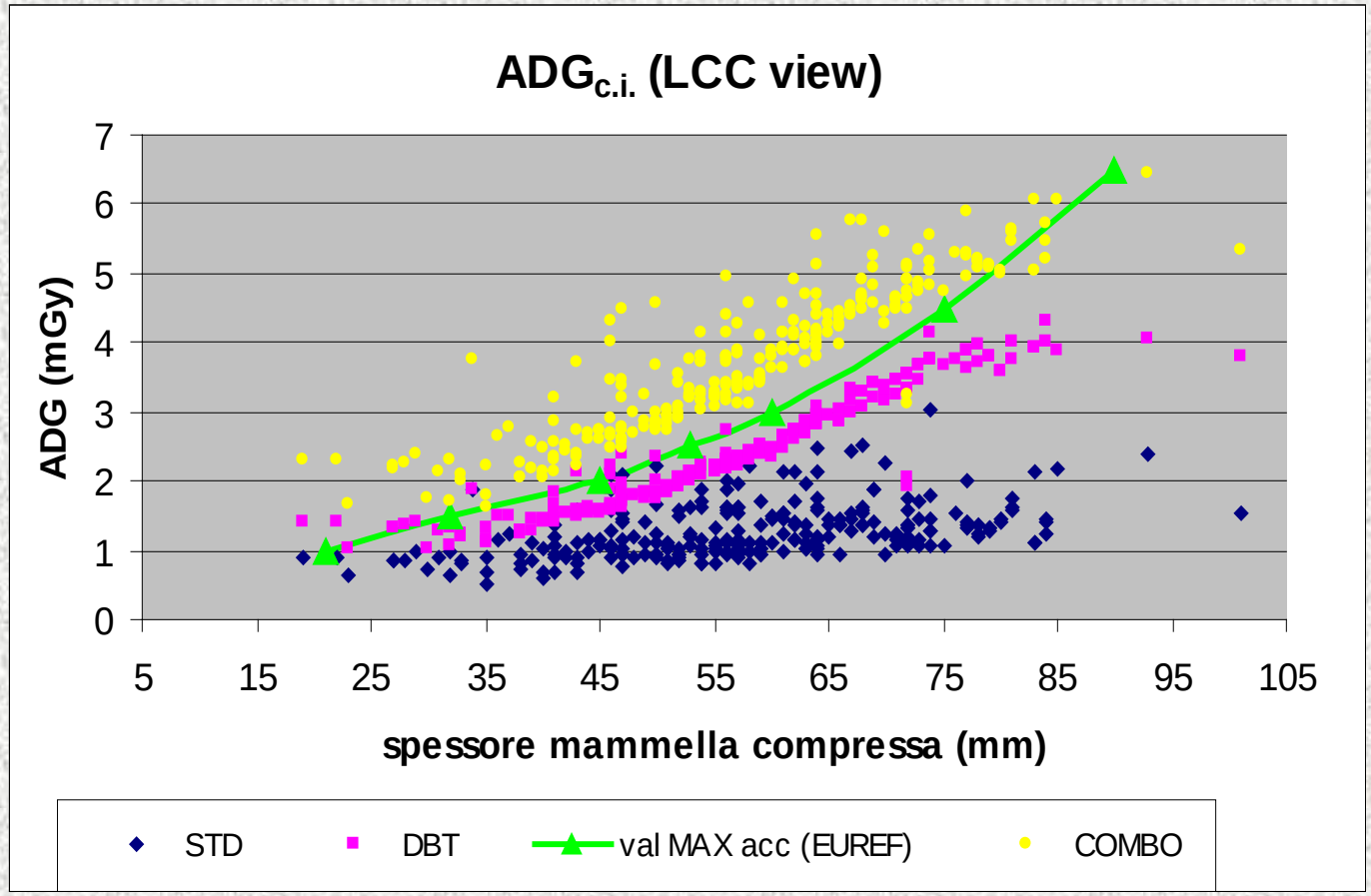

1. Estimation of percentage
field digital mammograph
categories.
Tagliafico AS, **Tagliafic**
Br J Radiol. 2013 Nov;86(103
PMID: 24029631 Free PM
Similar articles

2. 'In vivo' average glandula
tomosynthesis and full-fie
Cavagnetto F, Taccini G
Radiat Prot Dosimetry. 2013
PMID: 23734057
Similar articles

3. Mammographic density e
tomosynthesis using fully
Tagliafico A, **Tagliafico**
Calabrese M.
Eur Radiol. 2012 Jun;22(6):1
PMID: 22358426
Similar articles

4. One-to-one comparison
Tagliafico A, Astengo D,
Eur Radiol. 2012 Mar;22(3):5
PMID: 21987214
Similar articles

15. Atypical ductal hyperplasia diagnosed at 11-gauge vacuum-assisted breast biopsy performed on suspicious clustered microcalcifications: could patients without residual microcalcifications be manag
Villa
AJR A
PMID:
Simila

16. Brac
tract
Tagli
Eur R
PMID:
Simila

17. Brac
comp
Tagli
Br J R
PMID:
Simila

18. Incre
Tagli
Fero
Eur J
PMID:
Simila

19. MR i
expe
Tagli
Skele
PMID:
Simila

10. 'In vivo' average glandular dose evaluation: one-to-one comparison between digital breast tomosynthesis and full-field digital mammography.
Cavagnett
Radiat Prot
PMID: 2373
Similar artic

11. Comparati
tomosynth
T
B
P
S

12. D
fr
T
R
P
S

13. M
b
T
M
E
P
S

14. O
T
E
P
S

5. of ultrasound.
Tagliafico A, Truini M, Spina B, Cambiaso P, Zaottini F, Bignotti B, **Calabrese** M, Derchi LE, Martinoli C.
Eur Radiol. 2015 Sep;25(9):2764-70. doi: 10.1007/s00330-015-3645-z. Epub 2015 Mar 21.
PMID: 25794664
Similar articles

Characterisation of microcalcification clusters on 2D digital mammography (FFDM) and digital breast

1. Diagnostic performance of contrast-enhanced spectral mammography: Systematic review and meta-analysis.
Tagliafico AS, Bignotti B, Rossi F, Signori A, Sormani MP, Vadora F, **Calabrese** M, Houssami N.
Breast. 2016 May 6;28:13-19. doi: 10.1016/j.breast.2016.04.008. [Epub ahead of print]
PMID: 27161411
Similar articles

2. Adjunct Screening With Tomosynthesis or Ultrasound in Women With Mammography-Negative Dense Breasts: Interim Report of a Prospective Comparative Trial.
Tagliafico AS, **Calabrese** M, Mariscotti G, Durando M, Tosto S, Monetti F, Airaldi S, Bignotti B, Nori J, Bagni A, Signori A, Sormani MP, Houssami N.
J Clin Oncol. 2016 Mar 9. pii: JCO634147. [Epub ahead of print]
PMID: 26962097
Similar articles

3. Effects on short-term quality of life of vacuum-assisted breast biopsy: comparison between digital breast tomosynthesis and digital mammography.
Tagliafico A, Gristina L, Bignotti B, Valdora F, Tosto S, **Calabrese** M.
Br J Radiol. 2015;88(1056):20150593. doi: 10.1259/bjr.20150593. Epub 2015 Oct 14.
PMID: 26463101
Similar articles

4. Quantitative evaluation of background parenchymal enhancement (BPE) on breast MRI. A feasibility study with a semi-automatic and automatic software compared to observer-based scores.
Tagliafico A, Bignotti B, **Tagliafico** G, Tosto S, Signori A, **Calabrese** M.
Br J Radiol. 2015;88(1056):20150417. doi: 10.1259/bjr.20150417. Epub 2015 Oct 14.
PMID: 26462852

La Tomosintesi in Liguria

J Clin Oncol. 2016 Mar 9. pii: JCO634147. [Epub ahead of print]

Adjunct Screening With Tomosynthesis or Ultrasound in Women With Mammography-Negative Dense Breasts: Interim Report of a Prospective Comparative Trial.

Tagliafico AS[1], Calabrese M[1], Mariscotti G[1], Durando M[1], Tosto S[1], Monetti F[1], Airaldi S[1], Bignotti B[1], Nori J[1], Bagni A[1], Signori A[1], Sormani MP[1], Houssami N[2].

Author information

Abstract

PURPOSE: Debate on adjunct screening in women with dense breasts has followed legislation requiring that women be informed about their mammographic density and related adjunct imaging. Ultrasound or tomosynthesis can detect breast cancer (BC) in mammography-negative dense breasts, but these modalities have not been directly compared in prospective trials. We conducted a trial of adjunct screening to compare, within the same participants, incremental BC detection by tomosynthesis and ultrasound in mammography-negative dense breasts.

PATIENTS AND METHODS: Adjunct Screening With Tomosynthesis or Ultrasound in Women With Mammography-Negative Dense Breasts is a prospective multicenter study recruiting asymptomatic women with mammography-negative screens and dense breasts. Eligible women had tomosynthesis and physician-performed ultrasound with independent interpretation of adjunct imaging. Outcome measures included cancer detection rate (CDR), number of false-positive (FP) recalls, and incremental CDR for each modality; these were compared using McNemar's test for paired binary data in a preplanned interim analysis.

RESULTS: Among 3,231 mammography-negative screening participants (median age, 51 years; interquartile range, 44 to 78 years) with dense breasts, 24 additional BCs were detected (23 invasive): 13 tomosynthesis-detected BCs (incremental CDR, 4.0 per 1,000 screens; 95% CI, 1.8 to 6.2) versus 23 ultrasound-detected BCs (incremental CDR, 7.1 per 1,000 screens; 95% CI, 4.2 to 10.0), P = .006. Incremental FP recall occurred in 107 participants (3.33%; 95% CI, 2.72% to 3.96%). FP recall (any testing) did not differ between tomosynthesis (FP = 53) and ultrasound (FP = 65), P = .26; FP recall (biopsy) also did not differ between tomosynthesis (FP = 22) and ultrasound (FP = 24), P = .86.

CONCLUSION: The Adjunct Screening With Tomosynthesis or Ultrasound in Women With Mammography-Negative Dense Breasts' interim analysis shows that ultrasound has better incremental BC detection than tomosynthesis in mammography-negative dense breasts at a similar FP-recall rate. However, future application of adjunct screening should consider that tomosynthesis detected more than 50% of the additional BCs in these women and could potentially be the primary screening modality.

ASTOUND

BIRADS 3-4

La Tomosintesi nello screening

Lancet Oncol. 2013 Jun;14(7):583-9. doi: 10.1016/S1470-2045(13)70134-7. Epub 2013 Apr 25.

Integration of 3D digital mammography with tomosynthesis for population breast-cancer screening (STORM): a prospective comparison study.

Ciatto S, Houssami N, Bernardi D, Caumo F, Pellegrini M, Brunelli S, Tuttobene P, Bricolo P, Fantò C, Valentini M, Montemezzi S, Macaskill P.

UO Senologia Clinica e Screening Mammografico, Department of Diagnostics, Azienda Provinciale Servizi Sanitari, Trento, Italy.

INTERPRETATION: Integrated 2D and 3D mammography improves breast-cancer detection and has the potential to reduce false positive recalls. Randomised controlled trials are needed to compare integrated 2D and 3D mammography with 2D mammography for breast cancer screening.

Prospective trial comparing full-field digital mammography (FFDM) versus combined FFDM and tomosynthesis in a population-based screening programme using independent double reading with arbitration.

Skaane P, Bandos AI, Gullien R, Eben EB, Ekseth U, Haakenaasen U, Izadi M, Jebsen IN, Jahr G, Krager M, Hofvind S.

Department of Radiology, Oslo University Hospital, University of Oslo, Oslo, Norway. PERSKA@ous-hf.no

CONCLUSION: Double reading of 2D + 3D significantly improves the cancer detection rate in mammography screening.

KEY POINTS: • Tomosynthesis-based screening was successfully implemented in a large prospective screening trial. • Double reading of tomosynthesis-based examinations significantly reduced false-positive interpretations. • Double reading of tomosynthesis significantly increased the detection of invasive cancers.

Radiology. 2013 Jul 30. [Epub ahead of print]

Comparison of Tomosynthesis Plus Digital Mammography and Digital Mammography Alone for Breast Cancer Screening.

Haas BM, Kalra V, Geisel J, Raghu M, Durand M, Philpotts LE.

Department of Diagnostic Radiology, Yale University School of Medicine, PO Box 208042, New Haven, CT 06520-8042.

= .70).Conclusion:Patients undergoing tomosynthesis plus digital mammography had significantly lower screening recall rates. The greatest reductions were for those younger than 50 years and those with dense breasts. A nonsignificant 9.5% increase in cancer detection was observed in the tomosynthesis group.© RSNA, 2013.

La Tomosintesi nello screening

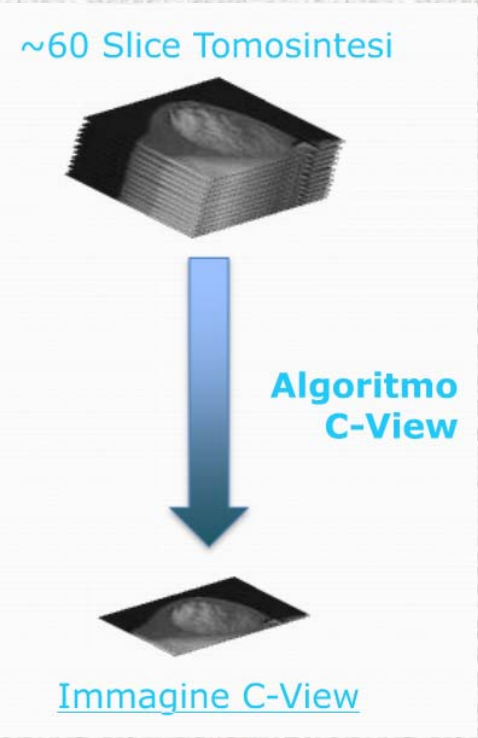

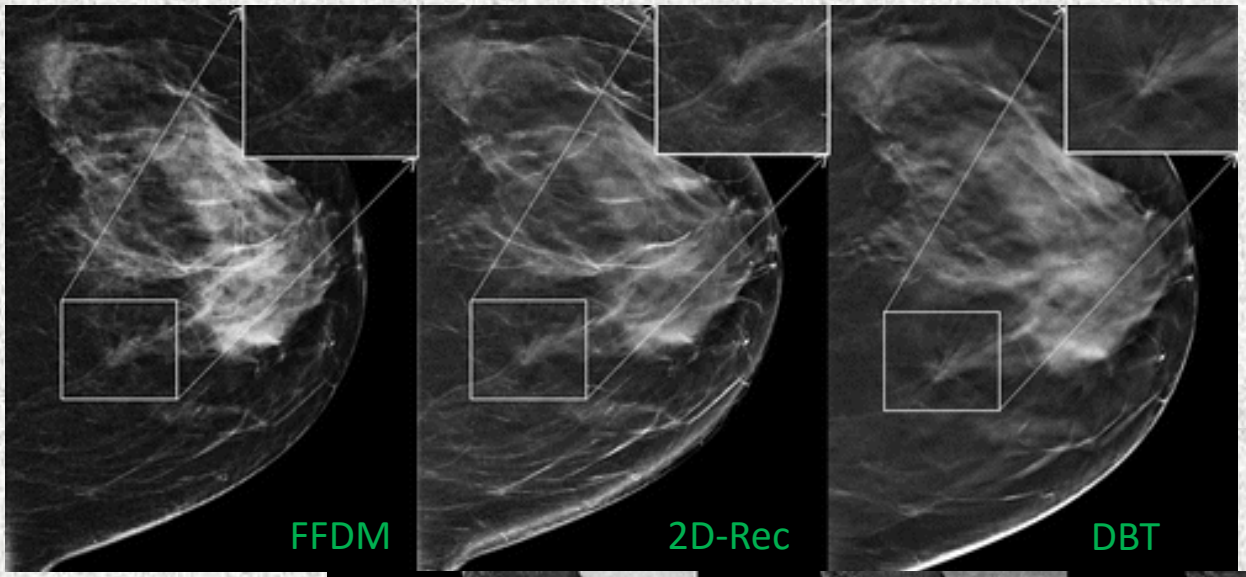

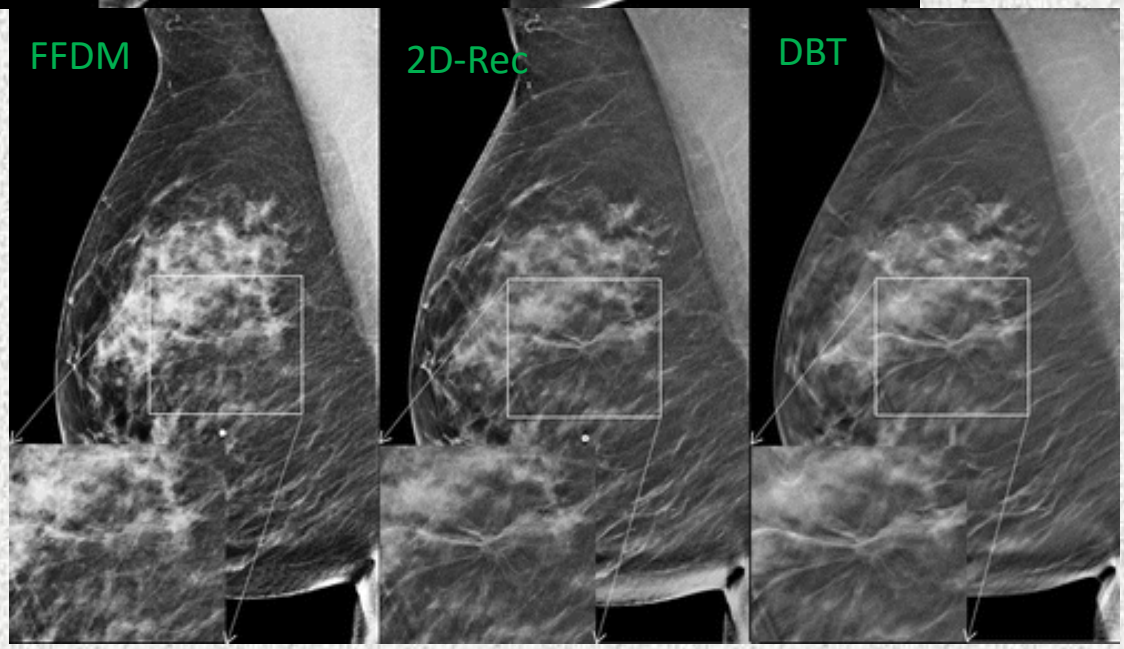

2D sintetica

CORSO PER TECNICI SANITARI DI RADIOLOGIA MEDICA E FISICI

La Tomosintesi nello screening

Acad Radiol. 2012 Feb;19(2):166-71. doi: 10.1016/j.acra.2011.10.003. Epub 2011 Nov 18.

Dose reduction in digital breast tomosynthesis (DBT) screening using synthetically reconstructed projection images: an observer performance study.

Gur D, Zuley ML, Anello MI, Rathfon GY, Chough DM, Ganott MA, Hakim CM, Wallace L, Lu A, Bandos AI.
University of Pittsburgh, Department of Radiology, Radiology Imaging Research, Pittsburgh, PA 15213, USA. gurd@upmc.edu

CONCLUSIONS: Lower sensitivity with comparable specificity was observed with the tested version of synthetically generated images compared to FFDM, both combined with DBT. Improved synthesized images with experimentally verified acceptable diagnostic quality will be needed to eliminate double exposure during DBT-based screening.

Radiology. 2014 Jun;271(3):655-63. doi: 10.1148/radiol.13131391. Epub 2014 Jan 24.

Two-view digital breast tomosynthesis screening with synthetically reconstructed projection images: comparison with digital breast tomosynthesis with full-field digital mammographic images.

Skaane P[1], Bandos AI, Eben EB, Jebsen IN, Krager M, Haakenaasen U, Ekseth U, Izadi M, Hofvind S, Gullien R.

Author information

Abstract

PURPOSE: To compare the performance of two versions of reconstructed two-dimensional (2D) images in combination with digital breast tomosynthesis (DBT) versus the performance of standard full-field digital mammography (FFDM) plus DBT.

CONCLUSION: The combination of current reconstructed 2D images and DBT performed comparably to FFDM plus DBT and is adequate for routine clinical use when interpreting screening mammograms.

La Tomosintesi nello screening

Breast Cancer
DOI 10.1007/s12282-016-0699-y

CrossMark

SPECIAL FEATURE

Possible supplemental breast cancer screening modalities

Breast cancer screening with digital breast tomosynthesis

Per Skaane[1]

CONCLUSION: The retrospective and the prospective screening studies comparing FFDM and DBT have all demonstrated that tomosynthesis has a great potential for improving breast cancer screening. DBT should be regarded as a better mammogram that could improve or overcome limitations of the conventional mammography, and tomosynthesis might be considered as the new technique in the next future of breast cancer screening.

Aprile 2016

VABB in Tomosintesi

- ✓ Da ottobre 2014
- ✓ Reperti sottoposti a biopsia: soprattutto distorsioni e cluster di microcalcificazioni
- ✓ Vantaggi:

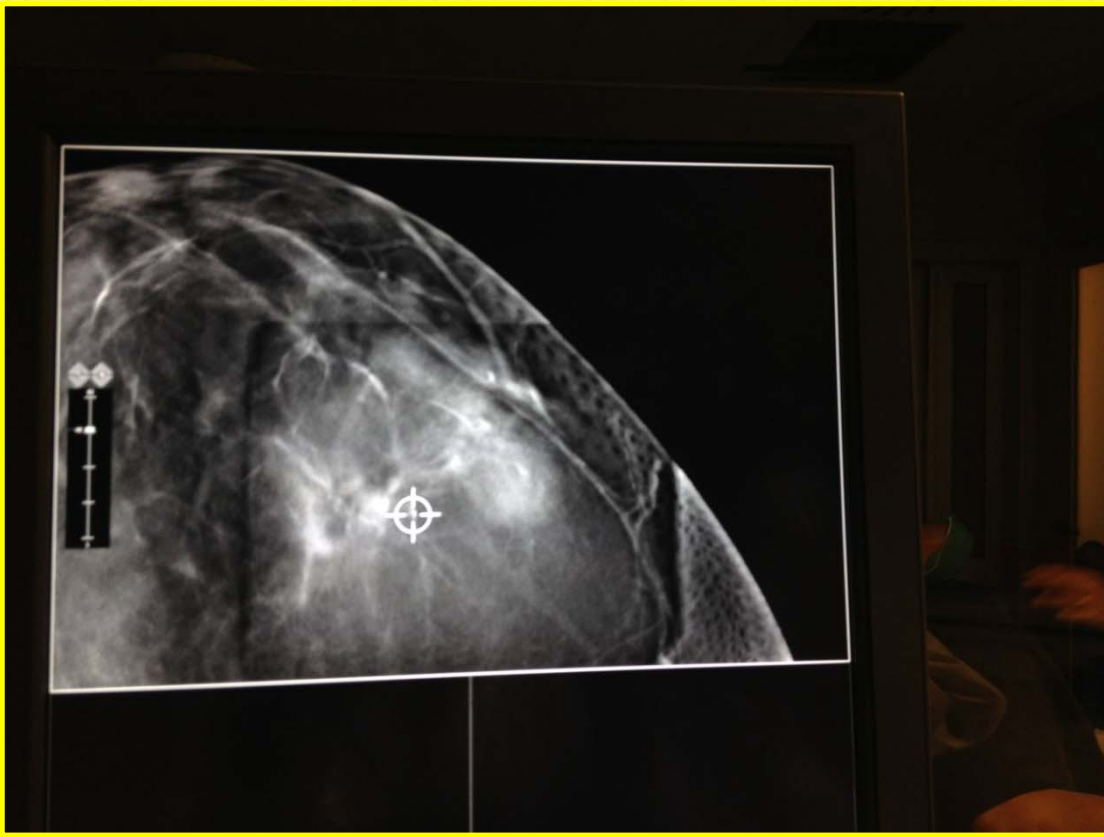

La Tomosintesi in Liguria

- **5 centri di screening uno per ASL**

- **3 tomosintesi (+ una – A.O.U.SanMartino IST)**

La Tomosintesi in Liguria

Centro	Anno install.	Utilizzo	Marca modello	C-View	Refertazione
ASL2	05/2013	II livello	Hologic Selenia Dimensions	no	Software dedicato
ASL3	07/2014	II livello -ASTOUND	Hologic Selenia Dimensions	Si, se solo Tomo e con combo per abituarsi	Software dedicato
ASL5	06/2014	II livello -ASTOUND	IMS Giotto Tomo	no	Software dedicato
A.O.U.San Martino-IST	07/2009	II livello fino 07/2014 -ASTOUND	Hologic Selenia Dimensions	Si, se solo tomo, a breve in clinica	Software dedicato

La Tomosintesi in Liguria

- **Obiettivo**: ottimizzare le prestazioni
  - Confronto DGM

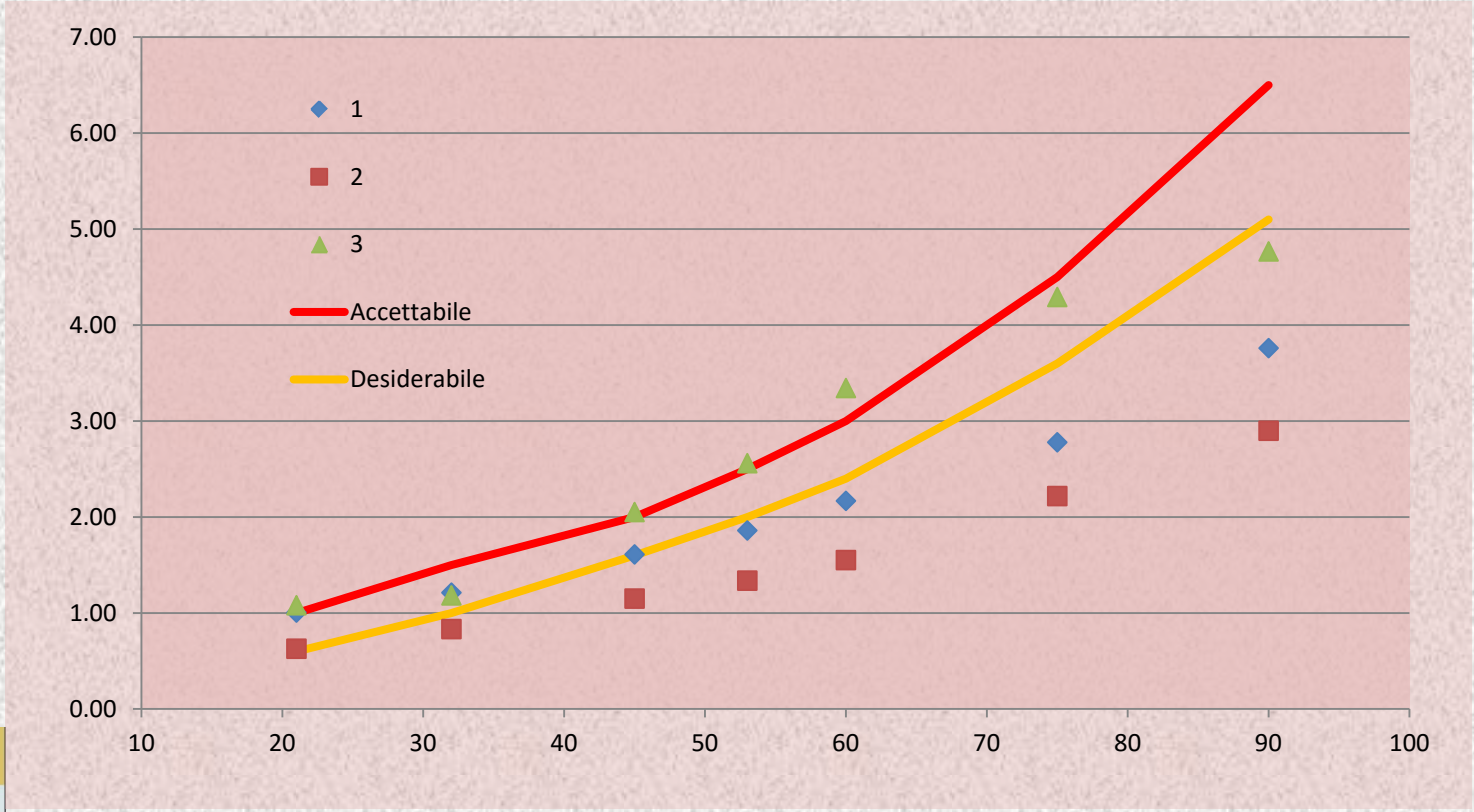

Contents lists available at ScienceDirect

The Breast

journal homepage: www.elsevier.com/brst

Review

Review of radiation dose estimates in digital breast tomosynthesis relative to those in two-view full-field digital mammography

T.M. Svahn [a, *], N. Houssami [a], I. Sechopoulos [b, c, d], S. Mattsson [e]

[a] School of Public Health, Sydney Medical School, University of Sydney, Sydney 2006, NSW, Australia
[b] Department of Radiology and Imaging Sciences, Emory University, 1701 Uppergate Drive Northeast, Suite 5018, Atlanta, GA 30322, USA
[c] Department of Hematology and Medical Oncology, Emory University, 1701 Uppergate Drive Northeast, Suite 5018, Atlanta, GA 30322, USA
[d] Winship Cancer Institute, Emory University, 1701 Uppergate Drive Northeast, Suite 5018, Atlanta, GA 30322, USA
[e] Medical Radiation Physics, Department of Clinical Sciences Malmö, Lund University, Skåne University Hospital, Malmö, Sweden

ARTICLE INFO

Article history:
Received 13 October 2014
Received in revised form
25 November 2014
Accepted 3 December 2014
Available online xxx

Keywords:
Digital breast tomosynthesis
Full-field digital mammography
Radiation doses to the breast

ABSTRACT

We examined how radiation dose levels in digital breast tomosynthesis (DBT) differ from those used in 2-view full-field digital mammography (FFDM).

Acquisition parameter settings and information on the average absorbed dose to the glandular tissues within the breasts were reviewed based on clinical studies that evaluated DBT and FFDM. Dose ratios (D_{DBT}/D_{FFDM}) were derived from imaging protocols, which included tomosynthesis in 1- or 2-views alone, and as an adjunct technique to FFDM.

Stand-alone DBT was associated with a much lower to a slightly higher radiation dose compared to that of comparable FFDM units, as summarized in dose ratio ranges of 0.34–1.0 for 1-view DBT, and 0.68–1.17 for 2-view DBT. One of the lowest reported dose estimates was obtained using a photon-counting DBT unit (avg. 0.70 mGy/scan; range: 0.28–1.26 mGy). Breast doses for DBT combined with FFDM are summarized in dose ratio ranges of 1.03–1.5 for 1-view DBT plus FFDM, and 2.0–2.23 for 2-view DBT plus FFDM. In the latter of these settings, the dose was reduced by ~45% when 2D-views, reconstructed from the DBT images ("synthetic 2D images"), were used as a substitute for FFDM.

Stand-alone DBT operated at lower to slightly higher radiation doses in comparison to FFDM. For DBT combined with FFDM, radiation doses were elevated, at maximum by a factor ~2 1/4 of that of FFDM alone. In this setting, a replacement of FFDM with synthetic 2D-views reduced the breast dose approximately by half, which has substantial implications for population screening programs.

Table A1
A description of different DBT and FFDM (SFM) systems used in clinical studies. The Siemens and GE systems were based on a stationary detector design, while the others systems used moving detectors. The DBT systems by Xcounter, Sectra (Philips) and GE used iterative reconstruction methods, while the other systems used filtered-back projection methods.

Study	Studies on DBT systems of various designs (2008–2014)						Comparative FFDM (SFM) systems
	Manufacturer	DBT unit (FFDM platform or clinical unit)	AEC	Detector technology/ Conversion of X-rays	Number of projections	Angular range (°)	
Gennaro et al. 2010 [21]	GE*	Senographe DS	No	CsI, amorphous silicon/Indirect	15	40	Senographe 2000D
Gennaro et al. 2013 [22]							Senographe 2000D
Thibault et al. 2013 [42]							Senographe DS/2000D
Svahn et al. 2010 [5]	Siemens*	Novation^{DR}	No	Amorphous selenium/Direct	25	50	Mamomat Novation^{DR}
Svahn et al. 2012 [37]							
Svane et al. 2010 [23]	Xcounter	Xmamo – 3T	No	48 parallel detector elements/ Photon-counting	26	26	FFDM: Giotto Image SDL, Giotto Image 3DL, Selenia, Senographe DS, Senographe Essential SFM: Diamond, Mammomat 3000
Wallis et al. 2012 [19]	Sectra (Philips)	MicroDose	Yes	Multislit (Si)/Photon-counting	21	11	MicroDose D40, Senographe DS, Senographe Essential
Zanca et al. 2012 [20]							
Good et al. 2008 [47] [a]	Hologic	Selenia	No	Amorphous selenium/Direct	11	15	–
Gur et al., 2009 [48] [a]							–
Teerstra et al. 2010 [49]							Selenia
Rafferty et al. 2013 [50]							Selenia
Rafferty et al. 2014 [33]							Selenia
Michell et al. 2012 [29] [b]	Hologic	Selenia Dimensions	Yes	Amorphous selenium/Direct	15	15	Selenia Dimensions
Waldherr et al. 2013 [51]							
Skaane et al. 2014 [6]							
Shin et al. 2014 [44]							

[a] In the studies by Good et al. [47] and Gur et al. [48] there was no specific information on the model/name of DBT or FFDM system(s) used, but technicalities of the DBT unit was the same as for the Hologic investigational unit based on the Selenia platform.
[b] In the study by Waldherr et al. [51] the system had similar technical description as the clinical unit, but the model/name was not presented.

Table 1B
Absorbed dose ratios (D_{DBT}/D_{FFDM}) and DBT systems used in clinical studies comparing DBT in one or in two views as an adjunct to mammography *versus* mammography only. D_{DBT} represents the total dose of the complete examination, so in this case, D_{DBT} includes the glandular dose estimates for the DBT acquisitions and the adjunct mammography acquisitions.

	Study	Dose ascertainment and/or dose estimate (see Methods)	Reported information on radiation dose	Dose ratio estimation (D_{DBT}/D_{FFDM})	Absorbed dose ratio (D_{DBT}/D_{FFDM})
One-view DBT	Gennaro et al. 2013	ii	DBT dose was within dose at 2-view SFM. D_{FFDM} was not presented	–	–
	Svahn et al. 2010	iii	Double the tube current-exposure time product was used of a single 2D-image dose, using the same tube voltage and anode/filter combination	$Dose_{min}\left(\frac{1view_{DBT}+1view_{FFDM}}{2view_{FFDM}}\right)=\frac{0.9+0.5}{1.0}=1.4$ $Dose_{max}\left(\frac{1view_{DBT}+1view_{FFDM}}{2view_{FFDM}}\right)=\frac{1.0+0.5}{1.0}=1.5$	~1.4–1.5
	Thibault et al. 2013	ii	DBT dose was within that of 2-view SFM. D_{FFDM} was not presented. D_{DBT} range: 1.9–7 mGy	–	–
	Waldherr et al. 2013	i	DBT dose/acquisition ~that of an FFDM image	$Dose\left(\frac{1view_{DBT}+2view_{FFDM}}{2view_{FFDM}}\right)=\frac{3.0}{2.0}=1.5$	~1.5
	Rafferty et al. 2014	iv	Dose for DBT + FFDM ~ twice that of FFDM	$Dose\left(\frac{1view_{DBT}+2view_{FFDM}}{2view_{FFDM}}\right)=\frac{3.0}{2.0}=1.5$	~1.5
	Shin et al. 2014	i, 2	The mean average glandular dose: FFDM: 1.63 mGy (0.68–7.41) DBT: 1.74 mGy (0.93–5.02 mGy)	$Dose\left(\frac{1view_{DBT}+1view_{FFDM}}{2view_{FFDM}}\right)=\frac{1.74+1.63}{1.63+1.63}=1.03$	~1.03
	Dose ratio range:				1.03–1.5
Two-view DBT	Gur et al. 2009	iv	DBT dose/acquisition ~ that of a mammogram	$\sim\frac{2.0}{1.0}$	~2.0
	Michell et al. 2012	iv, 1	FFDM: 1.37–1.57 mGy DBT: 1.66–1.90 mGy SFM dose was not presented	$Dose_{min}\left(\frac{2views(1.37+1.66)mGy}{2views\times1.37mGy}\right)=2.21$ $Dose_{max}\left(\frac{2views(1.57+1.90)mGy}{2views\times1.57mGy}\right)=2.21$	2.21
	Rafferty et al. 2013, 2014	iv	Dose for DBT + FFDM ~ twice that of FFDM	$\sim\frac{2.0}{1.0}$	~2.0
	Skaane et al. 2014	i, 2	Average dose (standard deviations): FFDM: 1.58 ± 0.61 DBT + FFDM: 3.52 ± 1.08	$\left(\frac{2views\times3.52mGy}{2views\times1.58mGy}\right)=2.23$	2.23
	Skaane et al. 2014	i, 2	Average dose (standard deviations): FFDM: 1.58 ± 0.61 DBT + synthetic 2D: 1.95 ± 0.58.	$\left(\frac{2views\times1.95mGy}{2views\times1.58mGy}\right)=1.23$	(1.23)
	Dose ratio range:				2.0–2.23

La Tomosintesi in Liguria

- **Obiettivo**: ottimizzare le prestazioni
  - Confronto **Controlli di Qualità**:
    - Protocollo comune
    - ……EUREF?
    - Semplificazione:
    - ***Tubo RX con diversa filtrazione***:
      - **Verifica stabilità:**
        - ❖Accuratezza
        - ❖Riproducibilità
        - ❖Rendimento
        - ❖SEV
        - ❖DGM

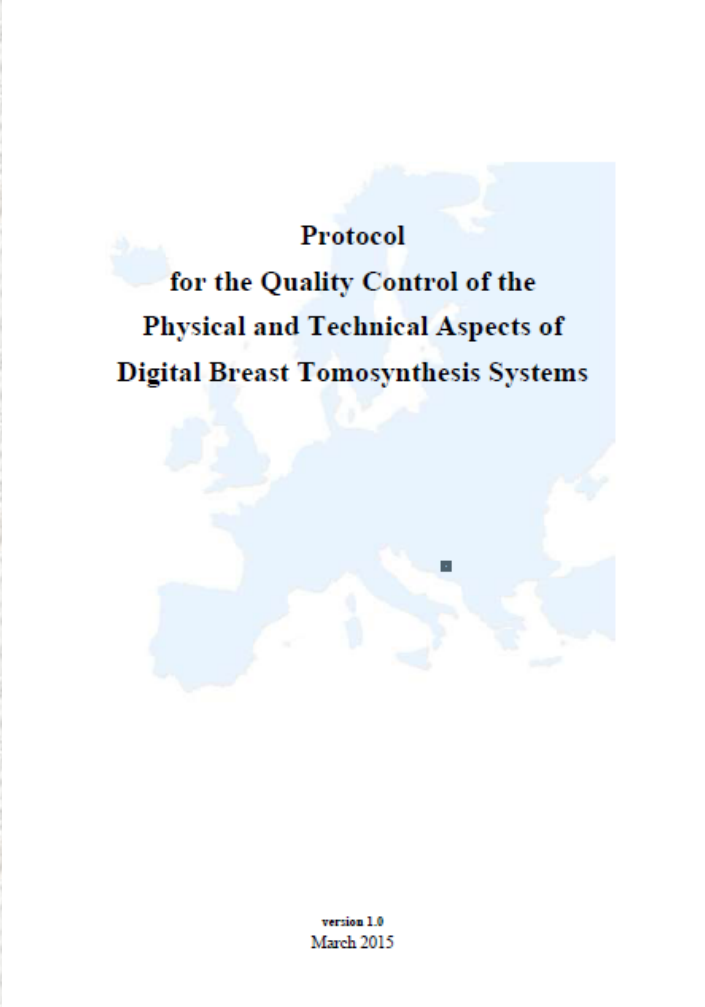
Protocol
for the Quality Control of the
Physical and Technical Aspects of
Digital Breast Tomosynthesis Systems

version 1.0
March 2015

La Tomosintesi in Liguria

Immagini ricostruite

- Fondamentale:
  - Controllare che dettagli posti ad una certa altezza nota **z**, ***nelle immagini ricostruite***, siano a fuoco nella sezione corretta
  - Geometria di ricostruzione corretta anche sul piano XY

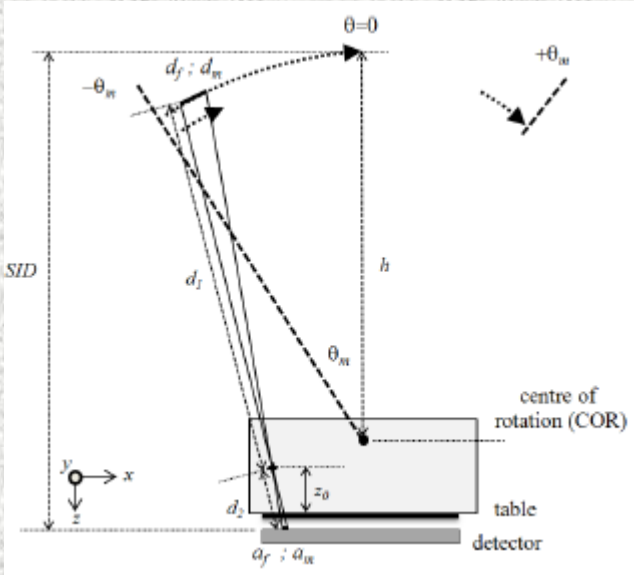

Immagini ricostruite

- ***Coincidenza tra volume ricostruito ed irradiato***
  - I due volumi possono non coincidere ai lati dove esistono volumi solo parzialmente irradiati
  - Controllo lato torace paziente, e lati detettore

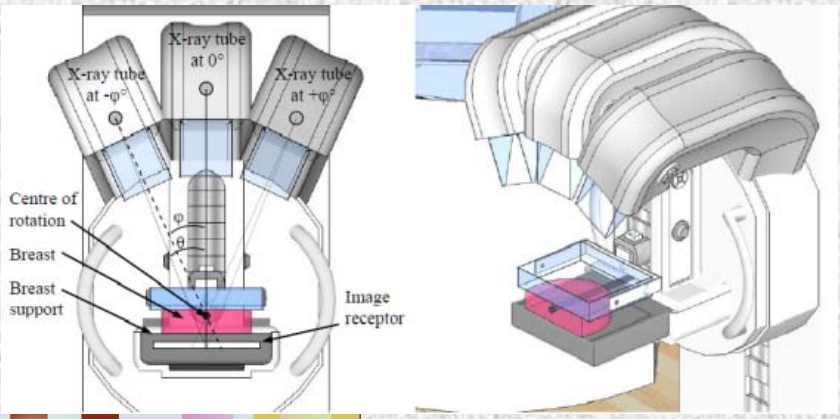

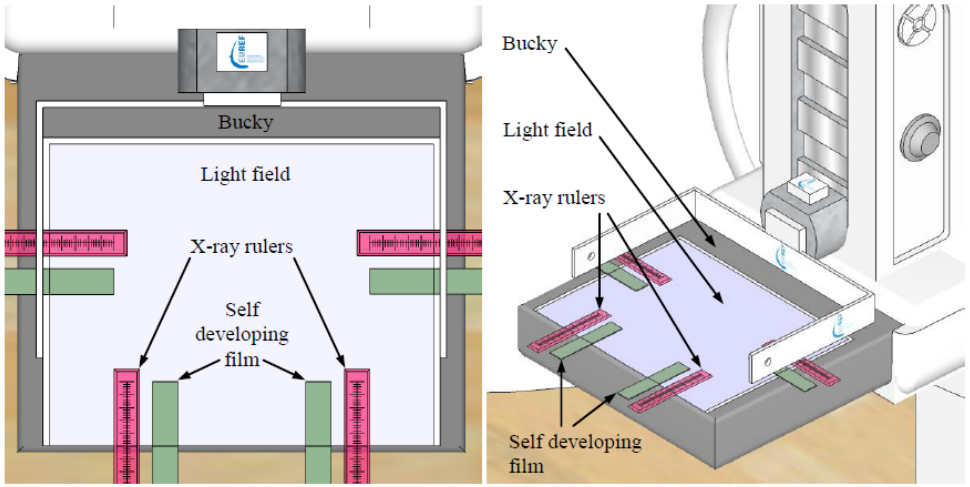

Figure 4 Set-up for measuring coincidence of reconstructed and irradiated volume on the bucky, top view and 3D view.

Immagini ricostruite

- ***Distorsione geometrica***
  - Immagini a diverse profondità
  - Controlli 3D
  - Sui tre piani X,Y,Z

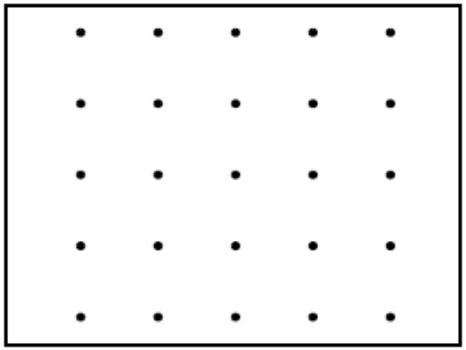

Figure 6a Phantom for evaluation of z-resolution; The phantom consists of a 5 mm thick PMMA slab with a rectangular array of 1mm diameter aluminium spheres embedded in the middle of the slab. The spheres are spaced at 55mm intervals with an accuracy of +/-0.1mm.

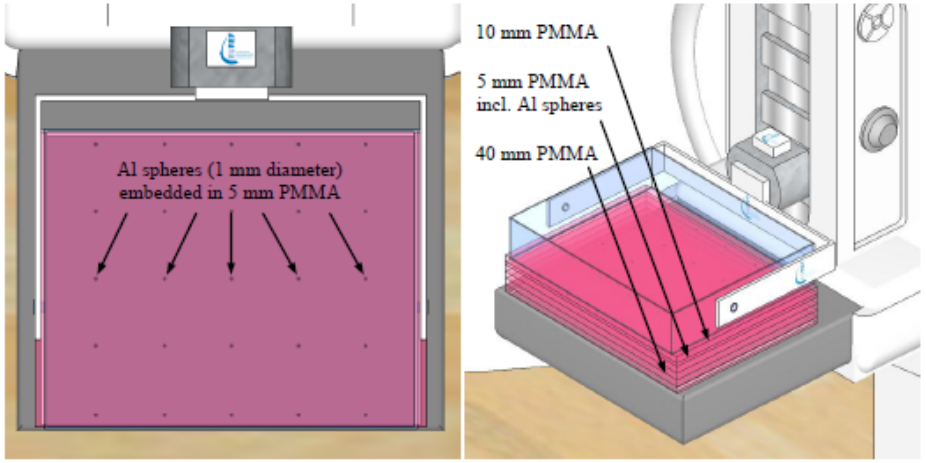

Figure 6b Setup for the evaluation of z-resolution (50mm PMMA + 5mm phantom), top view and 3D-view.

Immagini ricostruite

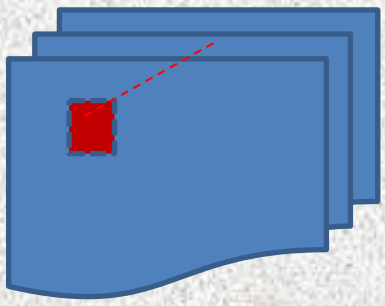

- ***Omogeneità***
  - PMMA block
  - ROI 5 x 5 mm
  - Media sui piani adiacenti (5 mm - cubo)
  - Media, SD e varianza -> SNR
  - …necessarie immagini…
  - …semplificazione:
    - Analisi omogeneità su due piani come 2D, a rotazione

Immagini ricostruite

- ***Qualità delle immagini ricostruite:***
  - CDMAMM: …analisi qualitativa sul piano dell'immagine a fuoco, cambiando altezza fantoccio

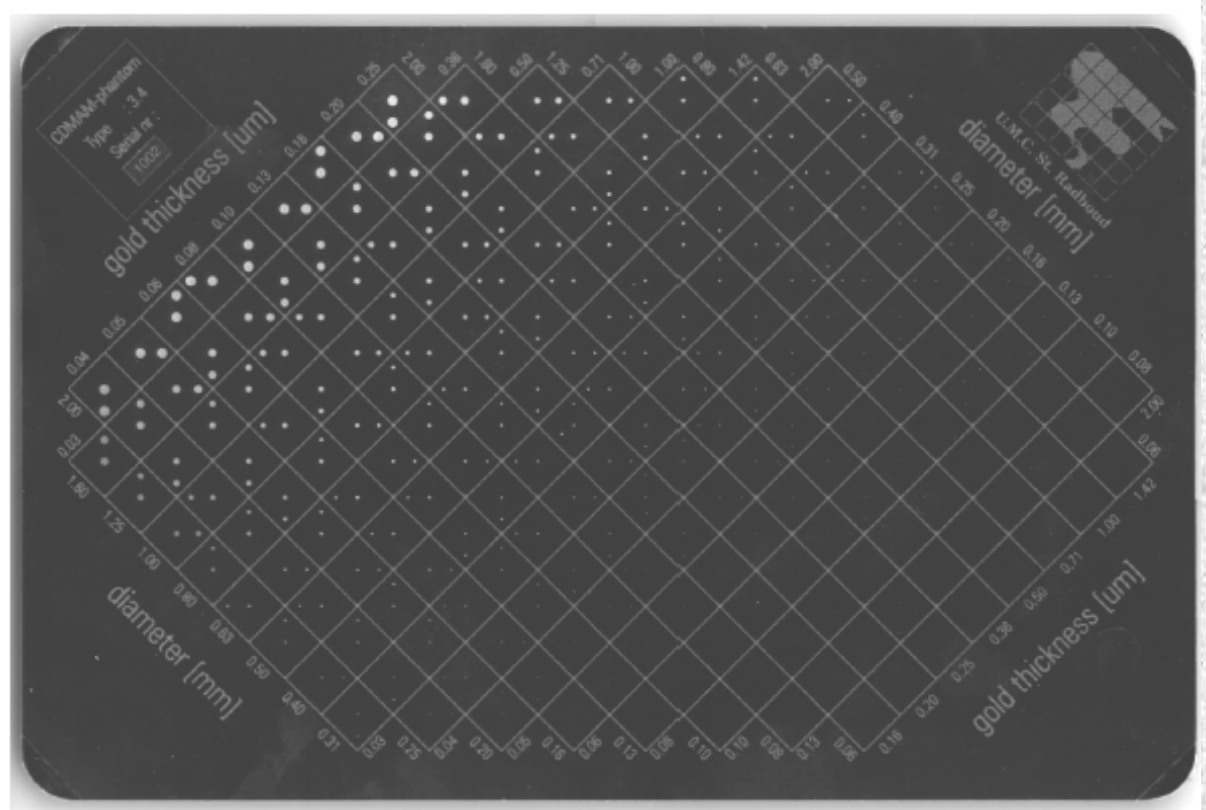

Immagini ricostruite

- ***Qualità delle immagini ricostruite:***
  - TORMAM, TORMAX, MEDITEST: …analisi qualitativa sul piano dell'immagine a fuoco, cambiando altezza

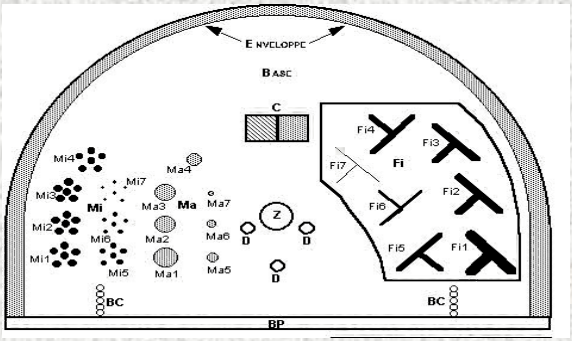



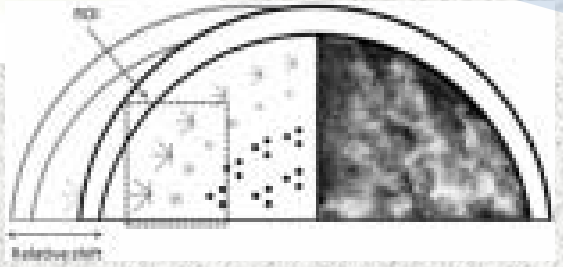

Costanza delle prestazioni

Conclusioni
Il futuribile

- La Tomosintesi si sta diffondendo nello screening
- Tendenza: primo livello in alcuni casi (seno denso)
- Tendenza: C-View in clinica

- Protocollo Garanzia della Qualità comune
- Confronto sulla qualità dell'immagine