GISMa 2016

Finalborgo, 20 maggio 2016

Cosa bolle in pentola

Esperienze di Automated Breast Volume Scanner (ABVS)

Esperienze di ecografia mammaria automatica volumetrica (EMAV)

Alfonso Frigerio

Franca Artuso

Luisella Milanesio

Valeria Selvestrel

alfonso.frigerio@gmail.com

GISMa 2016

Finalborgo, 18 maggio 2016

Workshop GISMa – ONS

Lo screening nelle donne giovani: va cambiato qualcosa?

Densità mammografica: riflessioni

* problemi

* protocolli

* nuove tecniche

Alfonso Frigerio

alfonso.frigerio@gmail.com

GISMa 2016

Finalborgo, 18 maggio 2016

Workshop GISMa – ONS / Lo screening nelle donne giovani / Diagnosi / **Densità mammografica: riflessioni**

il peccato originale dello screening mammografico / **la mammella densa**

Alfonso Frigerio

alfonso.frigerio@gmail.com

GISMa 2016

Finalborgo, 18 maggio 2016

Workshop GISMa – ONS

Lo screening nelle donne giovani: va cambiato qualcosa?

Densità mammografica: riflessioni * problemi

* impatto clinico-diagnostico, protocolli, nuove tecniche

Concetti di riferimento:

* prove scientifiche di efficacia

* fattibilità, sostenibilità

* costo/efficacia, **guadagno marginale**

Alfonso Frigerio

alfonso.frigerio@gmail.com

Tumori, 93: 562-566, 2007

NEGLIGIBLE ADVANTAGES AND EXCESS COSTS OF ROUTINE ADDITION OF BREAST ULTRASONOGRAPHY TO MAMMOGRAPHY IN DENSE BREASTS

Beniamino Brancato, Rita Bonardi, Sandra Catarzi, Chiara Iacconi, Gabriella Risso, Renzo Taschini, and Stefano Ciatto

Centro per lo Studio e la Prevenzione Oncologica, Florence, Italy

Aim: **To assess the role of breast ultrasonography as a complement to negative mammography in radiologically dense breasts.**
Material and methods: **Out of a total series of 49,044 consecutive mammograms reported as negative in asymptomatic women, 25,665 (52.3%) were coded as dense (BI-RADS D3-4) and ultrasonography was recommended. Due to organizational problems, ultrasonography was performed immediately or within 1 month only in 5,227 cases, representing the study series.**
Results: **Two cancers were detected at immediate ultrasonography (0.03%). The cancer detection rate in women aged 40-49 and 50-69 years was 0.002% and 0.07%, respectively. The benign biopsy rate was 0.5% for core biopsies and 0.02% for surgical biopsies. The cost per ultrasonography-assessed woman was € 56.05, whereas the cost per additional mammographically occult but ultrasonography-detected cancer was € 146,496.53. The mammograms of the 2 cancer cases underwent blind review by an expert reader and were confirmed as negative.**
Discussion: **Our findings show a low cancer detection rate, substantially lower compared to other clinical studies of ultrasonography in dense breasts, though in accordance with preliminary evidence from an Italian randomized clinical trial within a population-based screening program. The policy of adding ultrasonography to negative mammography in dense breasts seems to have very limited cost-effectiveness, and should not be adopted in routine practice before results of ongoing clinical trials are available.**

Key words: breast cancer, mammography, radiologically dense breast, screening, ultrasonography.

Abstract ~

Full text links

THE LANCET

Lancet. 2016 Jan 23;387(10016):341-8. doi: 10.1016/S0140-6736(15)00774-6. Epub 2015 Nov 5.

Sensitivity and specificity of mammography and adjunctive ultrasonography to screen for breast cancer in the Japan Strategic Anti-cancer Randomized Trial (J-START): a randomised controlled trial.

Ohuchi N[1], Suzuki A[2], Sobue T[3], Kawai M[4], Yamamoto S[5], Zheng YF[2], Shiono YN[2], Saito H[5], Kuriyama S[6], Tohno E[7], Endo T[8], Fukao A[9], Tsuji I[10], Yamaguchi T[11], Ohashi Y[12], Fukuda M[13], Ishida T[2]; J-START investigator groups.

Author information

Abstract

BACKGROUND: Mammography is the only proven method for breast cancer screening that reduces mortality, although it is inaccurate in young women or women with dense breasts. We investigated the efficacy of adjunctive ultrasonography.

METHODS: Between July, 2007, and March, 2011, we enrolled asymptomatic women aged 40-49 years at 42 study sites in 23 prefectures into the Japan Strategic Anti-cancer Randomized Trial (J-START). Eligible women had no history of any cancer in the previous 5 years and were expected to live for more than 5 years. Randomisation was done centrally by the Japan Clinical Research Support Unit. Participants were randomly assigned in 1:1 ratio to undergo mammography and ultrasonography (intervention group) or mammography alone (control group) twice in 2 years. The primary outcome was sensitivity, specificity, cancer detection rate, and stage distribution at the first round of screening. Analysis was by intention to treat. This study is registered, number UMIN000000757.

FINDINGS: Of 72,998 women enrolled, 36,859 were assigned to the intervention group and 36,139 to the control group. Sensitivity was significantly higher in the intervention group than in the control group (91·1%, 95% CI 87·2-95·0 vs 77·0%, 70·3-83·7; p=0·0004), whereas specificity was significantly lower (87·7%, 87·3-88·0 vs 91·4%, 91·1-91·7; p<0·0001). More cancers were detected in the intervention group than in the control group (184 [0·50%] vs 117 [0·32%], p=0·0003) and were more frequently stage 0 and I (144 [71·3%] vs 79 [52·0%], p=0·0194). 18 (0·05%) interval cancers were detected in the intervention group compared with 35 (0·10%) in the control group (p=0·034).

INTERPRETATION: Adjunctive ultrasonography increases sensitivity and detection rate of early cancers.

FUNDING: Ministry of Health, Labour and Welfare of Japan.

Comment in

Adding ultrasound to mammography could increase breast cancer detection in Asian women.

Screening su misura / personalizzato?

l’idea di screening personalizzato è certo attraente
e parte da considerazioni in sè del tutto ragionevoli

p.es.:

i “seni densi” sono più difficili da interpretare,
quindi in questi casi aggiungo alla mammografia
l’esame clinico e/o l’ecografia,
… e/o la tomosintesi,
… e/o l’ecografia automatica

Screening personalizzato?
l'esempio delle cattedrali

- rischi da evitare in uno screening personalizzato:
  - il progetto manca l'obiettivo di copertura della popolazione
  - i fondi non sono sufficienti
  - le risorse materiali ed umane disponibili non sono sufficienti
  - progetto costruito su modelli troppo ambiziosi, non riproducibili
  - > progetto con aspetti logistico-gestionali complessi (?)
  - >> fattibilità (?)
  - >> sostenibilità (??)

screening personalizzato?
l’esempio delle cattedrali

- lo screening come una cattedrale
  - Firenze e Siena

GISMa 2016

Finalborgo, 20 maggio 2016

Cosa bolle in pentola

Esperienze di Ecografia Mammaria Automatica Volumetrica (EMAV)

- EMAV – che cos'è? come funziona?
- EMAV – ha un posto nello screening?

- tecnica di esecuzione
- tempi di esecuzione
- curva di apprendimento
- tempi di lettura
- validità scientifica / applicabilità allo screening

GISMa 2016

Finalborgo, 20 maggio 2016

Cosa bolle in pentola

Esperienze di Ecografia Mammaria Automatica Volumetrica (EMAV)

GISMa 2016

Finalborgo, 20 maggio 2016

Cosa bolle in pentola

Esperienze di Ecografia Mammaria Automatica Volumetrica (EMAV)

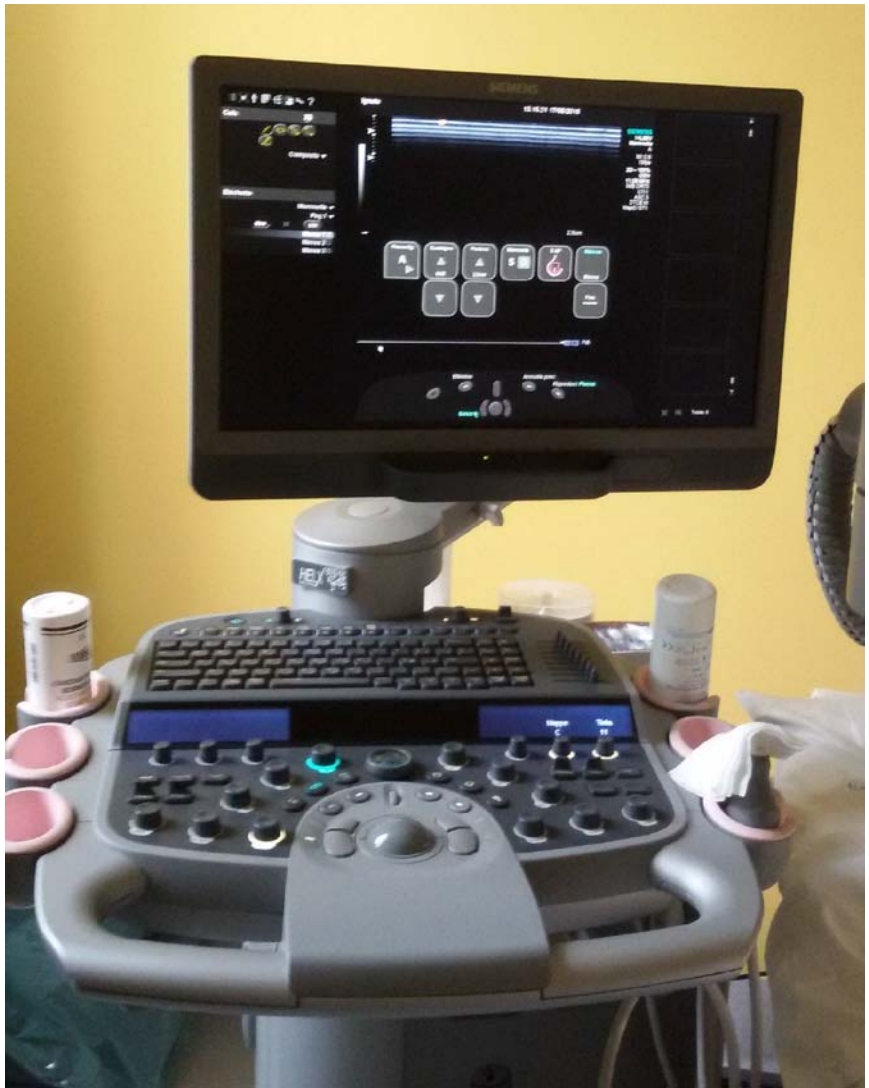


SIEMENS
SIEMENS



- EMAV – ha un posto nello screening?

- tecnica di esecuzione

  – eseguita dal TSRM
  – relativamente facile/riproducibile, ma non banale
  – **maggiore completezza, sistematicità del campo esaminato**

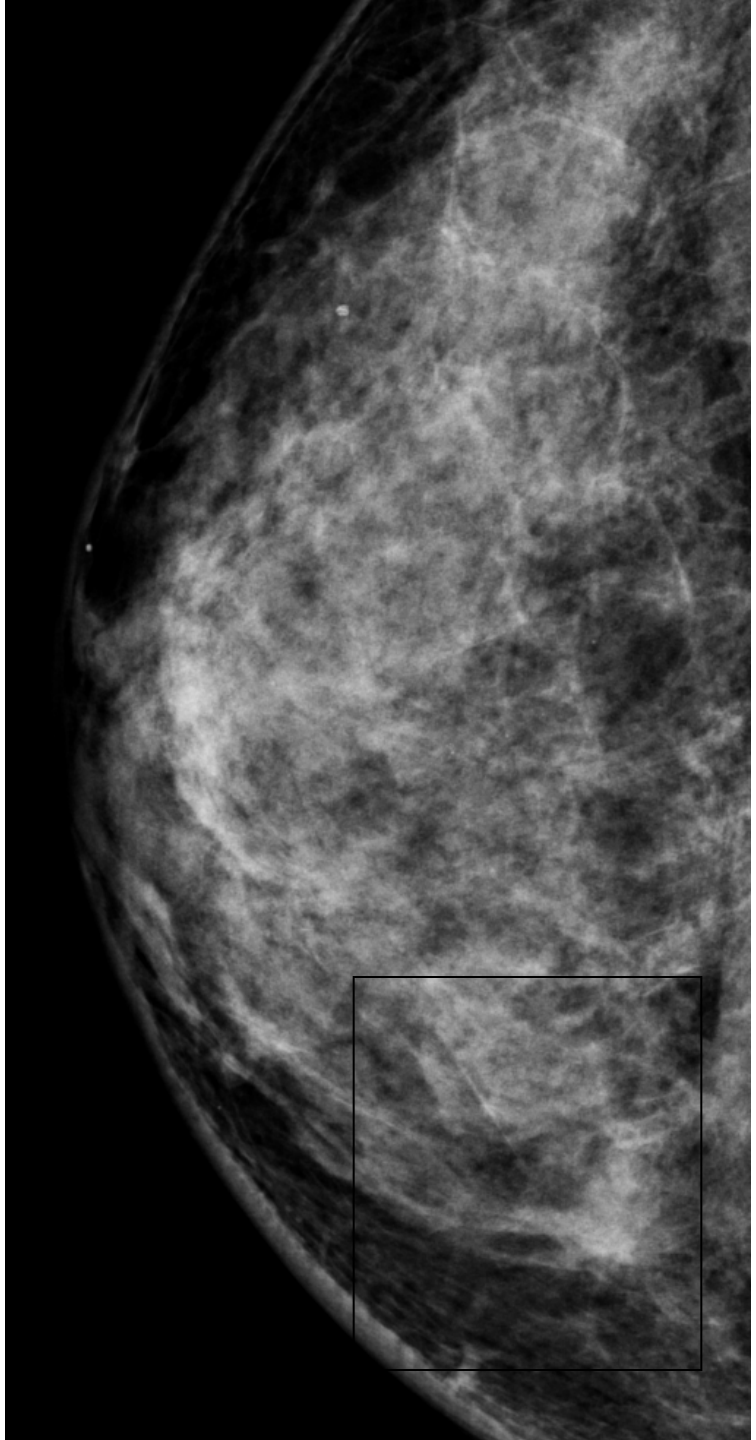

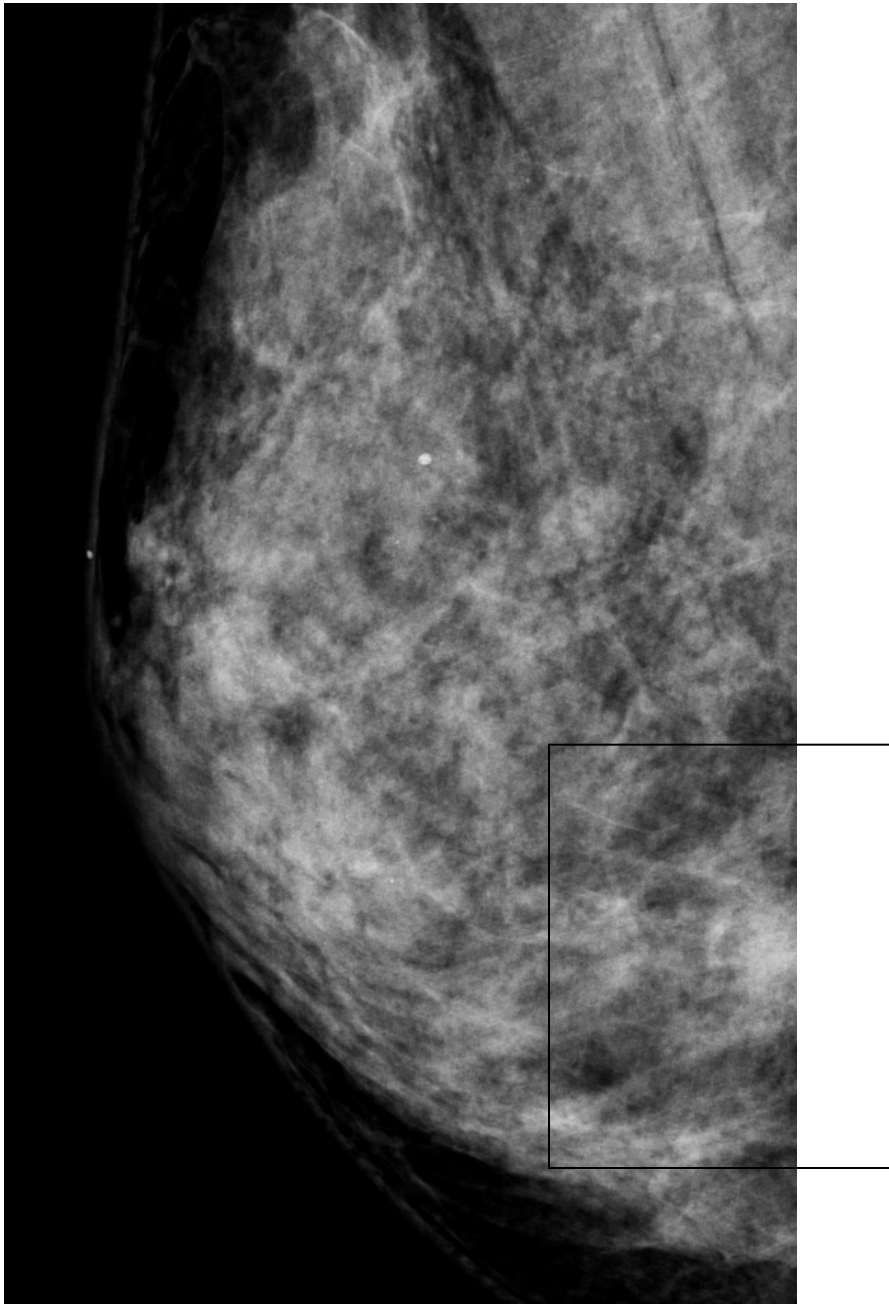

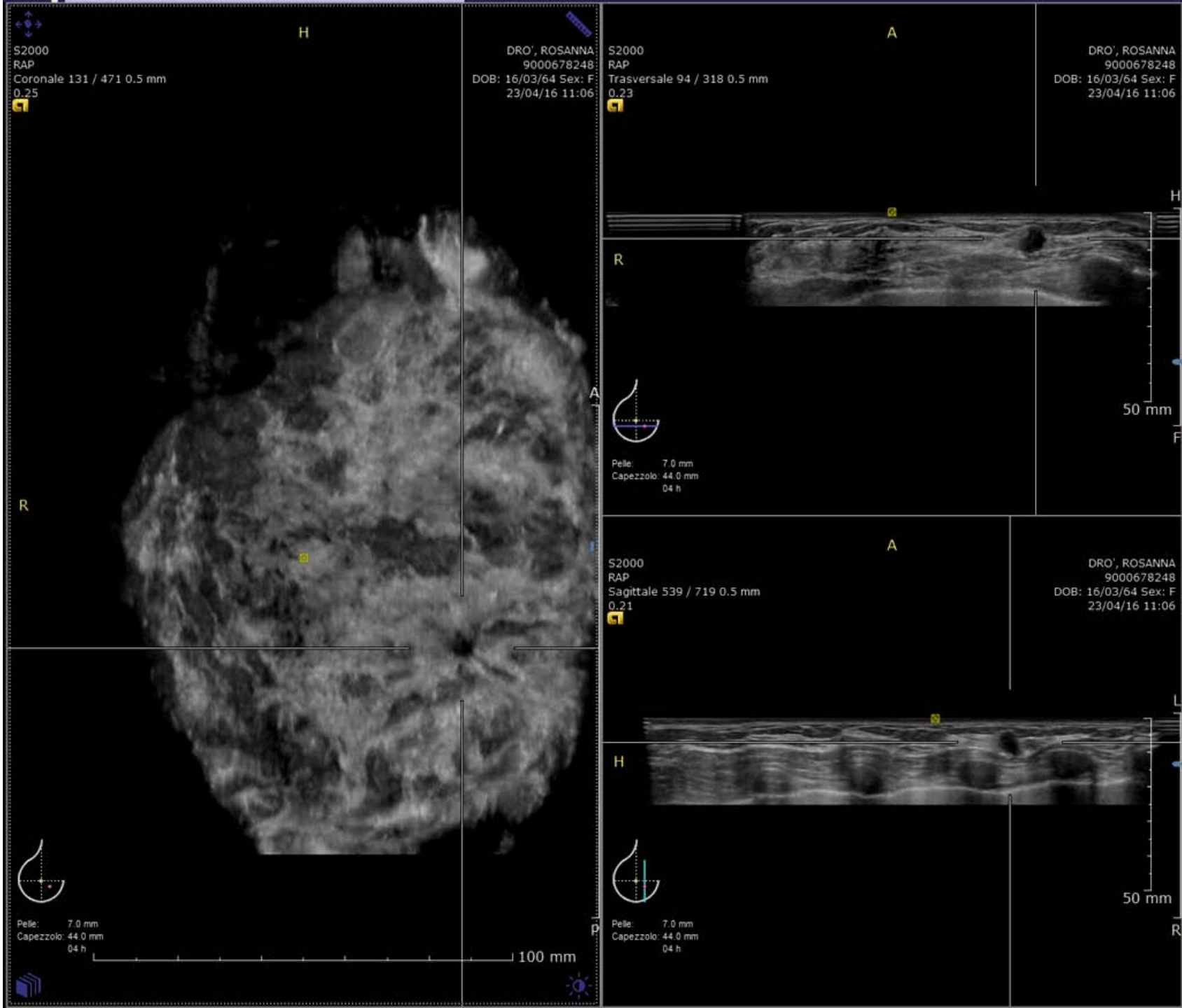
H
S2000
RAP
Coronale 131 / 471 0.5 mm
0.25
DRO', ROSANNA
9000678248
DOB: 16/03/64 Sex: F
23/04/16 11:06
A
R
P
Pelle: 7.0 mm
Capezzolo: 44.0 mm
04 h
100 mm
A
S2000
RAP
Trasversale 94 / 318 0.5 mm
0.23
DRO', ROSANNA
9000678248
DOB: 16/03/64 Sex: F
23/04/16 11:06
H
R
F
50 mm
Pelle: 7.0 mm
Capezzolo: 44.0 mm
04 h
A
S2000
RAP
Sagittale 539 / 719 0.5 mm
0.21
DRO', ROSANNA
9000678248
DOB: 16/03/64 Sex: F
23/04/16 11:06
L
H
R
50 mm
Pelle: 7.0 mm
Capezzolo: 44.0 mm
04 h

- EMAV – ha un posto nello screening?

- tempo di esecuzione

GISMa 2016

Finalborgo, 20 maggio 2016

Cosa bolle in pentola

Esperienze di Ecografia Mammaria Automatica Volumetrica (EMAV)

- EMAV – ha un posto nello screening?
- tempo di esecuzione
  - minimo 3 scansioni per lato \ 6 in totale
  - 30”-75’’ / scansione
  - **10’-15’ tempo totale di esame**
  - **nettamente superiore a quello di una mammografia e/o tomosintesi**
  - **studio di percorsi/flussi di lavoro**
  - selezione dei casi

GISMa 2016

Finalborgo, 20 maggio 2016

Cosa bolle in pentola

Esperienze di Ecografia Mammaria Automatica Volumetrica (EMAV)

- EMAV – ha un posto nello screening?

- tempo di lettura / curva di apprendimento

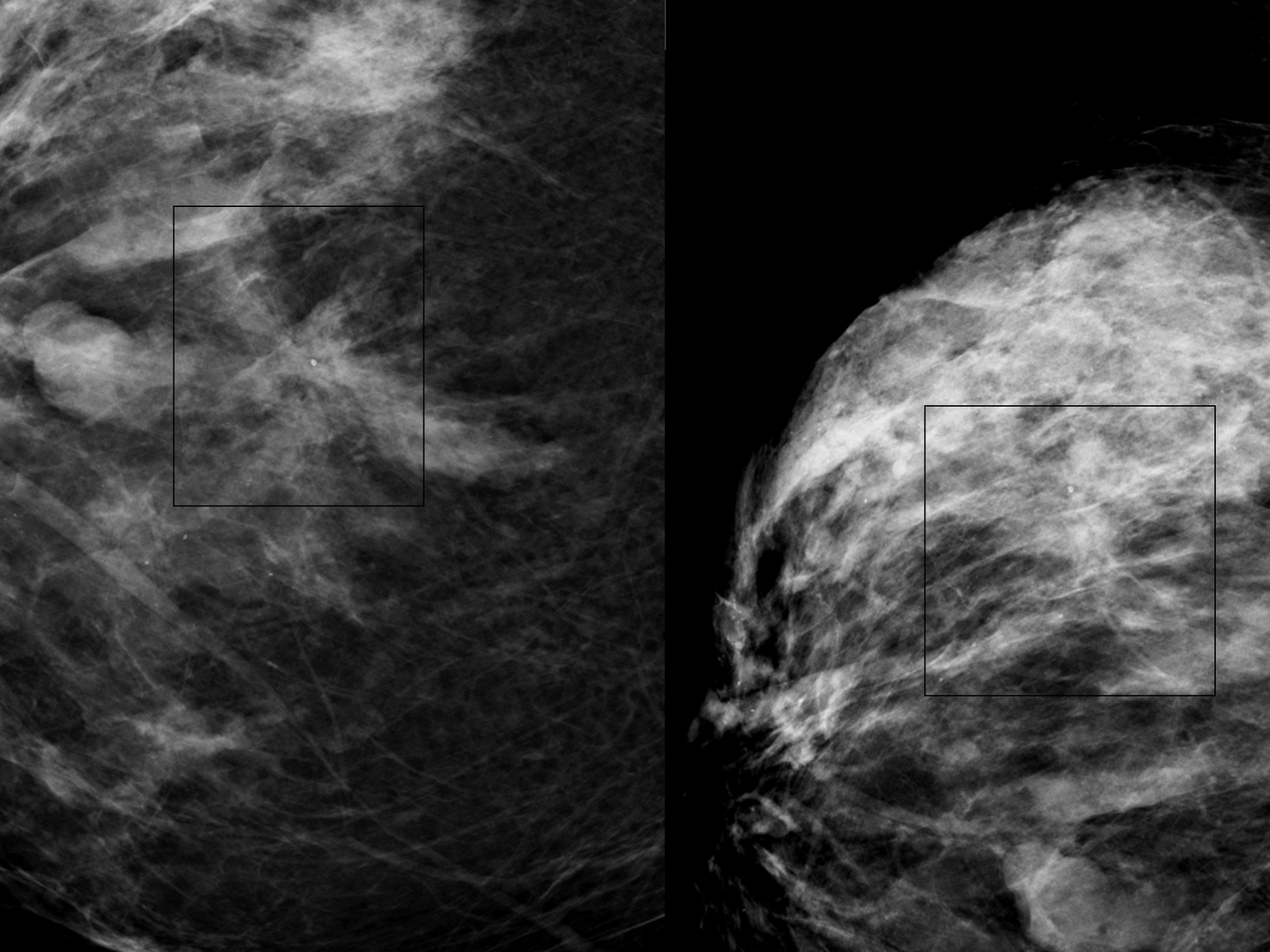

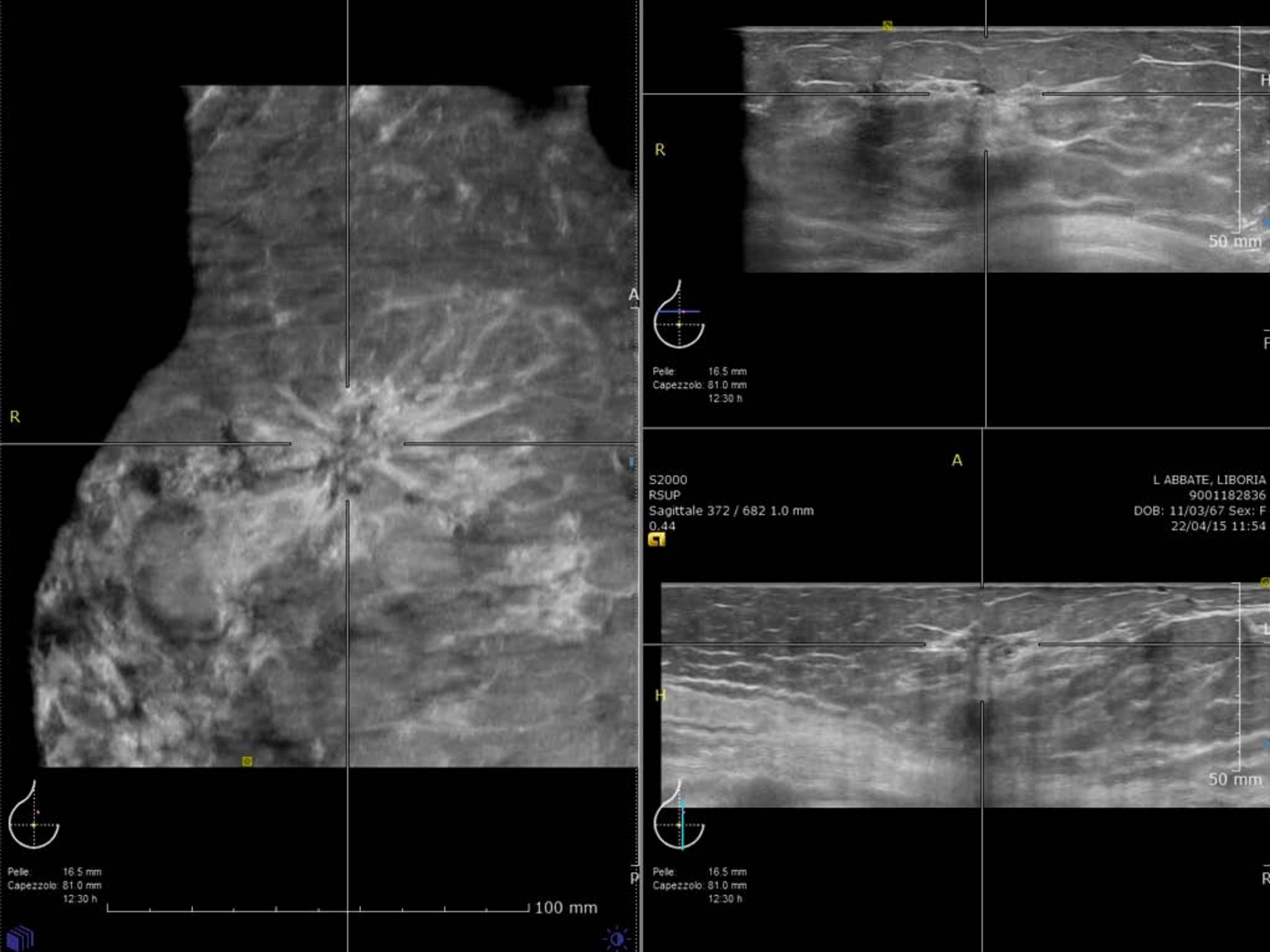
R
A
P
Pelle: 16.5 mm
Capezzolo: 81.0 mm
12:30 h
100 mm
R
H
50 mm
Pelle: 16.5 mm
Capezzolo: 81.0 mm
12:30 h
A
S2000
RSUP
Sagittale 372 / 682 1.0 mm
0.44
L ABBATE, LIBORIA
9001182836
DOB: 11/03/67 Sex: F
22/04/15 11:54
H
50 mm
Pelle: 16.5 mm
Capezzolo: 81.0 mm
12:30 h
R

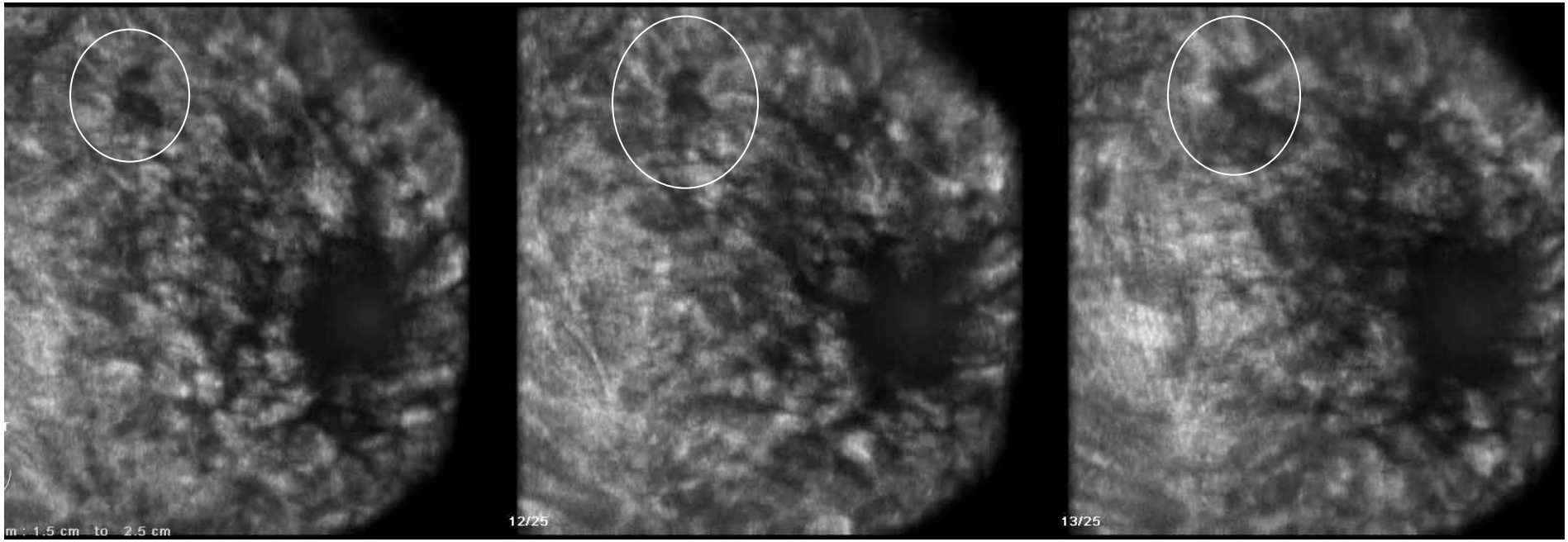
m : 1.5 cm to 2.5 cm
12/25
13/25

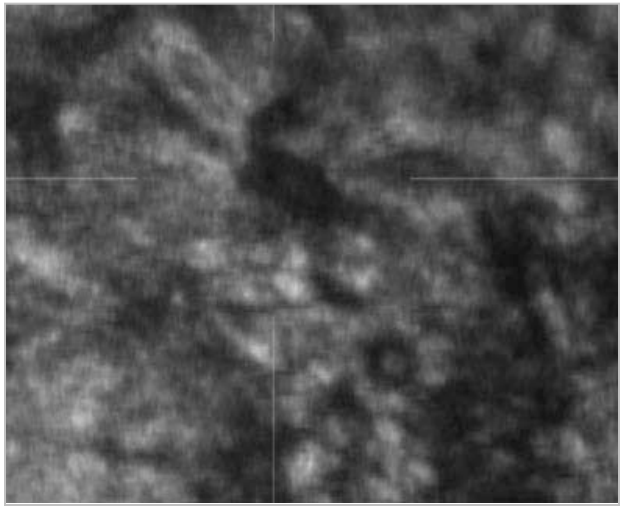

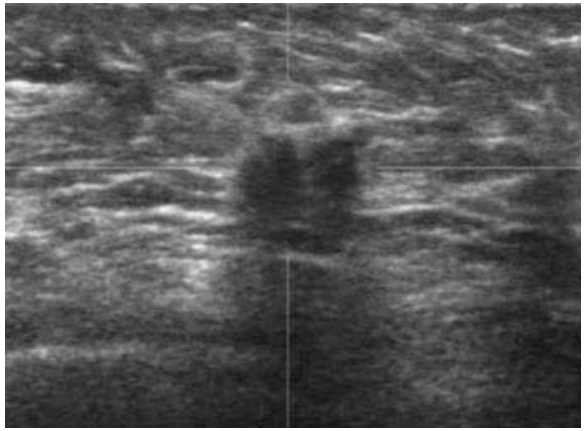

GISMa 2016

Finalborgo, 20 maggio 2016

Cosa bolle in pentola

Esperienze di Ecografia Mammaria Automatica Volumetrica (EMAV)

- EMAV – ha un posto nello screening?
- tempo di lettura / curva di apprendimento
  - incremento netto sul protocollo normale
  - necessità di CAD
  - utilizzo di piani di scansione inconsueti
  - curva di apprendimento

- EMAV – ha un posto nello screening? (1)

- validità scientifica

Maryellen L. Giger[1]
Marc F. Inciardi[2]
Alexandra Edwards[1]
John Papaioannou[1]
Karen Drukker[1]
Yulei Jiang[1]
Rachel Brem[3]
Jeremy Bancroft Brown[1]

Automated Breast Ultrasound in Breast Cancer Screening of Women With Dense Breasts: Reader Study of Mammography-Negative and Mammography-Positive Cancers

AJR 2016; 206:1–10

Alfonso Frigerio
alfonso.frigerio@gmail.com

Maryellen L. Giger[1]
Marc F. Inciardi[2]
Alexandra Edwards[1]
John Papaioannou[1]
Karen Drukker[1]
Yulei Jiang[1]
Rachel Brem[3]
Jeremy Bancroft Brown[1]

Automated Breast Ultrasound in Breast Cancer Screening of Women With Dense Breasts: Reader Study of Mammography-Negative and Mammography-Positive Cancers

AJR 2016; 206:1–10

MATERIALS AND METHODS. In this multireader, multicase, sequential-design reader study, 17 Mammography Quality Standards Act–qualified radiologists interpreted a cancer-enriched set of FFDM and ABUS examinations. All imaging studies were of asymptomatic women with BI-RADS C or D breast density. Readers first interpreted FFDM alone and subsequently interpreted FFDM combined with ABUS. The analysis included 185 cases: 133 noncancers and 52 biopsy-proven cancers. Of the 52 cancer cases, the screening FFDM images were interpreted as showing BI-RADS 1 or 2 findings in 31 cases and BI-RADS 0 findings in 21 cases. For the cases interpreted as BI-RADS 0, a forced BI-RADS score was also given. Reader performance was compared in terms of AUC under the ROC curve, sensitivity, and specificity.

- studio di lettura su casistica
- multicentrico
- serie di 185 casi con 52 cancri

Maryellen L. Giger[1]
Marc F. Inciardi[2]
Alexandra Edwards[1]
John Papaioannou[1]
Karen Drukker[1]
Yulei Jiang[1]
Rachel Brem[3]
Jeremy Bancroft Brown[1]

Automated Breast Ultrasound in Breast Cancer Screening of Women With Dense Breasts: Reader Study of Mammography-Negative and Mammography-Positive Cancers

AJR 2016; 206:1–10

RESULTS. The AUC was 0.72 for FFDM alone and 0.82 for FFDM combined with ABUS, yielding a statistically significant 14% relative improvement in AUC (i.e., change in AUC = 0.10 [CI, 0.07–0.14]; $p < 0.001$). When a cutpoint of BI-RADS 3 was used, the sensitivity across all readers was 57.5% for FFDM alone and 74.1% for FFDM with ABUS, yielding a statistically significant increase in sensitivity ($p < 0.001$) (relative increase = 29%). Overall specificity was 78.1% for FFDM alone and 76.1% for FFDM with ABUS ($p = 0.496$). For only the mammography-negative cancers, the average AUC was 0.60 for FFDM alone and 0.75 for FFDM with ABUS, yielding a statistically significant 25% relative improvement in AUC with the addition of ABUS ($p < 0.001$).

- lettura di mammografia (MD) / mammografia + ecografia automatica (EMAV)
  - aumento di sensibilità: 29 %
    - specificità invariata

All readers participated in ABUS training via online webinars and an in-person 1-day training session before the reader study. Each reader passed a skill test consisting of 25 cases including 10 biopsy-confirmed cancers, 10 biopsy-confirmed benign lesions, and five negative cases. Training was performed using the same electronic case report form used to record the readers' interpretations during the actual reader study.

TABLE 2: Multicase Multireader Performance Analysis: AUC Under the ROC Curve, Sensitivity, and Specificity for Full-Field Digital Mammography (FFDM) Alone and for FFDM With Automated Breast Ultrasound (ABUS) and the 95% CI for the Impact of ABUS Interpretation (Sequential Effect) and Associated *p* Value

Metric and Dataset	Value for FFDM Alone	Value for FFDM With ABUS	Change in Value With Addition of ABUS	Relative Change in Value (%)	95% CI for Sequential Effect	*p*[a]
AUC						
52 Cancers vs 133 noncancers	0.72	0.82	0.10	14	0.07–0.14	< 0.001
31 Mammography-negative cancers vs 133 noncancers	0.60	0.75	0.15	25	0.09–0.19	< 0.001
16 Mammography-negative cancers without prior breast interventions	0.57	0.78	0.21	36.8	0.10–0.33	< 0.001
21 Mammography-positive cancers vs 133 noncancers	0.89	0.94	0.05	5.6	0.01–0.09	0.002
Sensitivity[b] (%)						
52 Cancers	57.5	74.1	16.6	29	6.9–26.8	< 0.001
31 Mammography-negative cancers	38.5	62.4	23.9	62	10.3–37.4	0.004
16 Mammography-negative cancers without prior breast interventions	32.4	68.1	35.7	110	17.5–55.3	< 0.001
21 Mammography-positive cancers	85.4	91.3	5.9	6.9	–3.5 to 15.8[c]	0.234
Specificity[b] (%)						
133 Noncancers	78.1	76.2	–1.9	–2.4	–7.9 to 4.3[d]	0.496

Rachel F. Brem, MD
László Tabár, MD
Stephen W. Duffy, MSc
Marc F. Inciardi, MD
Jessica A. Guingrich, MD
Beverly E. Hashimoto, MD
Marla R. Lander, MD
Robert L. Lapidus, MD
Mary Kay Peterson, MD
Jocelyn A. Rapelyea, MD
Susan Roux, MD
Kathy J. Schilling, MD
Biren A. Shah, MD
Jessica Torrente, MD
Ralph T. Wynn, MD
Dave P. Miller, MS

Assessing Improvement in Detection of Breast Cancer with Three-dimensional Automated Breast US in Women with Dense Breast Tissue: The SomoInsight Study[1]

Radiology 2015; 274:663–673

Assessing Improvement in Detection of Breast Cancer with Three-dimensional Automated Breast US in Women with Dense Breast Tissue: The SomoInsight Study[1]

Purpose: To determine improvement in breast cancer detection by using supplemental three-dimensional (3D) automated breast (AB) ultrasonography (US) with screening mammography versus screening mammography alone in asymptomatic women with dense breasts.

Materials and Methods: Institutional review board approval and written informed consent were obtained for this HIPAA-compliant study. The SomoInsight Study was an observational, multicenter study conducted between 2009 and 2011. A total of 15318 women (mean age, 53.3 years ± 10 [standard deviation]; range, 25–94 years) presenting for screening mammography alone with heterogeneously (50%–75%) or extremely (>75%) dense breasts were included, regardless of further risk characterization, and were followed up for 1 year. Participants underwent screening mammography alone followed by an AB US examination; results were interpreted sequentially. McNemar test was used to assess differences in cancer detection.

Results: Breast cancer was diagnosed at screening in 112 women: 82 with screening mammography and an additional 30 with AB US. Addition of AB US to screening mammography yielded an additional 1.9 detected cancers per 1000 women screened (95% confidence interval [CI]: 1.2, 2.7; $P < .001$). Of cancers detected with screening mammography, 62.2% (51 of 82) were invasive versus 93.3% (28 of 30) of additional cancers detected with AB US ($P = .001$). Of the 82 cancers detected with either screening mammography alone or the combined read, 17 were detected with screening mammography alone. Of these, 64.7% (11 of 17) were ductal carcinoma in situ versus 6.7% (two of 30) of cancers detected with AB US alone. Sensitivity for the combined read increased by 26.7% (95% CI: 18.3%, 35.1%); the increase in the recall rate per 1000 women screened was 284.9 (95% CI: 278.0, 292.2; $P < .001$).

Conclusion: Addition of AB US to screening mammography in a generalizable cohort of women with dense breasts increased the cancer detection yield of clinically important cancers, but it also increased the number of false-positive results.

- studio osservazionale multicentrico

Assessing Improvement in Detection of Breast Cancer with Three-dimensional Automated Breast US in Women with Dense Breast Tissue: The SomoInsight Study[1]

Materials and Methods: Institutional review board approval and written informed consent were obtained for this HIPAA-compliant study. The SomoInsight Study was an observational, multicenter study conducted between 2009 and 2011. A total of 15318 women (mean age, 53.3 years ± 10 [standard deviation]; range, 25–94 years) presenting for screening mammography alone with heterogeneously (50%–75%) or extremely (>75%) dense breasts were included, regardless of further risk characterization, and were followed up for 1 year. Participants underwent screening mammography alone followed by an AB US examination; results were interpreted sequentially. McNemar test was used to assess differences in cancer detection.

- studio osservazionale multicentrico
  - 15318 donne di screening
- alta densità mammografica (> 50%)
- lettura sequenziale DM / DM+EMAV
  - follow-up di 1 anno

Assessing Improvement in Detection of Breast Cancer with Three-dimensional Automated Breast US in Women with Dense Breast Tissue: The SomoInsight Study[1]

Table 3

Results in 15318 Patients Screened Sequentially with Mammography Alone versus 3D AB US with Screening Mammography

Statistical Data	Screening Mammography Alone	Combined Screening Mammography and AB US Read	Difference*
No. of women recalled	2301	4364	2063
No. of cancers found	82	112	30
Yield per 1000 women screened	5.4 (4.2, 6.6)	7.3 (5.9, 8.7)	1.9 (1.2, 2.7)
Sensitivity at study entry (%)	73.2 (64.9, 81.7)	100	26.7 (18.3, 35.1)
PPV_1 (%)†	3.6 (82/2301)	2.6 (112/4364)	−1.0
95% CI	32.8, 4.4	2.1, 3.1	−1.4, −0.6
No. of women not recalled	13017	10954	2063
No. of noncancers in women not recalled (n = 15206)‡	12987	10954	2033
Specificity (%)	85.4 (84.9, 86.0)	72.0 (71.3, 72.7)	−13.4 (−14.0, −12.8)
No. of women recalled per 1000 women screened	150.2 (144.1, 155.7)	284.9 (278.0, 292.2)	134.6 (128.4, 141.0)
No. with biopsy recommended	610	1179	569
Per 1000 women screened	39.8 (36.7, 43.2)	77.0 (72.9, 81.0)	37.1 (34.0, 40.3)
PPV_2 (%)†	13.4 (82/610)	9.5 (112/1179)	−3.9
95% CI	10.7, 16.2	7.8, 11.3	−5.5, −2.3
No. with biopsy performed	586	1138	552
Per 1000 women screened	38.3 (35.3, 41.5)	74.3 (70.4, 78.2)	36.0 (32.9, 39.2)
PPV_3 (%)†	14.0 (82/586)	9.8 (112/1138)	−4.1
95% CI	11.2, 16.8	8.1, 11.7	−5.7, −2.5

Assessing Improvement in Detection of Breast Cancer with Three-dimensional Automated Breast US in Women with Dense Breast Tissue: The SomoInsight Study[1]

- Among the 82 cancers detected by using either screening mammography alone or the combined read, 17 were detected with screening mammography alone, 30 were detected with AB US alone, and 65 were detected with both screening mammography and AB US.
- Of cancers detected with screening mammography, 62.2% (51 of 82) were invasive versus 93.3% (28 of 30) of additional cancers detected with AB US ($P = .001$).
- Of the 17 cancers detected with screening mammography alone, 64.7% (11 of 17) were ductal carcinoma in situ versus 6.7% (two of 30) of cancers detected with AB US alone.

Assessing Improvement in Detection of Breast Cancer with Three-dimensional Automated Breast US in Women with Dense Breast Tissue: The SomoInsight Study[1]

- aumento di sensibilità: 27 %
  - specificità critica

Results: Breast cancer was diagnosed at screening in 112 women: 82 with screening mammography and an additional 30 with AB US. Addition of AB US to screening mammography yielded an additional 1.9 detected cancers per 1000 women screened (95% confidence interval [CI]: 1.2, 2.7; $P < .001$). Of cancers detected with screening mammography, 62.2% (51 of 82) were invasive versus 93.3% (28 of 30) of additional cancers detected with AB US ($P = .001$). Of the 82 cancers detected with either screening mammography alone or the combined read, 17 were detected with screening mammography alone. Of these, 64.7% (11 of 17) were ductal carcinoma in situ versus 6.7% (two of 30) of cancers detected with AB US alone. Sensitivity for the combined read increased by 26.7% (95% CI: 18.3%, 35.1%); the increase in the recall rate per 1000 women screened was 284.9 (95% CI: 278.0, 292.2; $P < .001$).

Conclusion: Addition of AB US to screening mammography in a generalizable cohort of women with dense breasts increased the cancer detection yield of clinically important cancers, but it also increased the number of false-positive results.

- EMAV – ha un posto nello screening? (1)

- validità scientifica

  – sensibilità eccellente
  – problema di specificità (?)
  – sviluppo di competenza
  – curve di apprendimento

- EMAV – ha un posto nello screening? (2)

- applicabilità allo screening
  - sensibilità eccellente
  - problema di specificità (?)
  - necessità di nuovi studi /dati
  - formazione
  - richiede una **innovazione pesante** nei percorsi / flussi di lavoro screening
  - **risorse / personale (TSRM e medico)**
  - **risorse** apparecchiature / **archiviazione / flussi informatici (RIS / PACS / workstation integrate)**

GISMa 2016

Finalborgo, 20 maggio 2016

Cosa bolle in pentola

Esperienze di Ecografia Mammaria Automatica Volumetrica (EMAV)

- EMAV – ha un posto nello screening? (2)

- applicabilità allo screening
  - sensibilità eccellente
  - problema di specificità (?)
  - **necessità di nuovi studi /dati**
    - **studi collaborativi prospettici in centri di screening di alto flusso**
    - **confronto MD, DBT, EMAV**
    - **valutazione fattibilità, costo/efficacia**
    - **studio di strategie / protocolli innovativi di selezione casi e flussi di lavoro**
  - formazione
  - richiede una innovazione pesante nei percorsi / flussi di lavoro screening
  - risorse / personale (TSRM e medico)
  - risorse apparecchiature / archiviazione / flussi informatici (RIS / PACS / workstation integrate)

GISMa 2016

Finalborgo, 20 maggio 2016

Cosa bolle in pentola

Esperienze di Ecografia Mammaria Automatica Volumetrica (EMAV)

Alfonso Frigerio

alfonso.frigerio@gmail.com