


CONVEGNO NAZIONALE **GISMA** 2014



Salerno

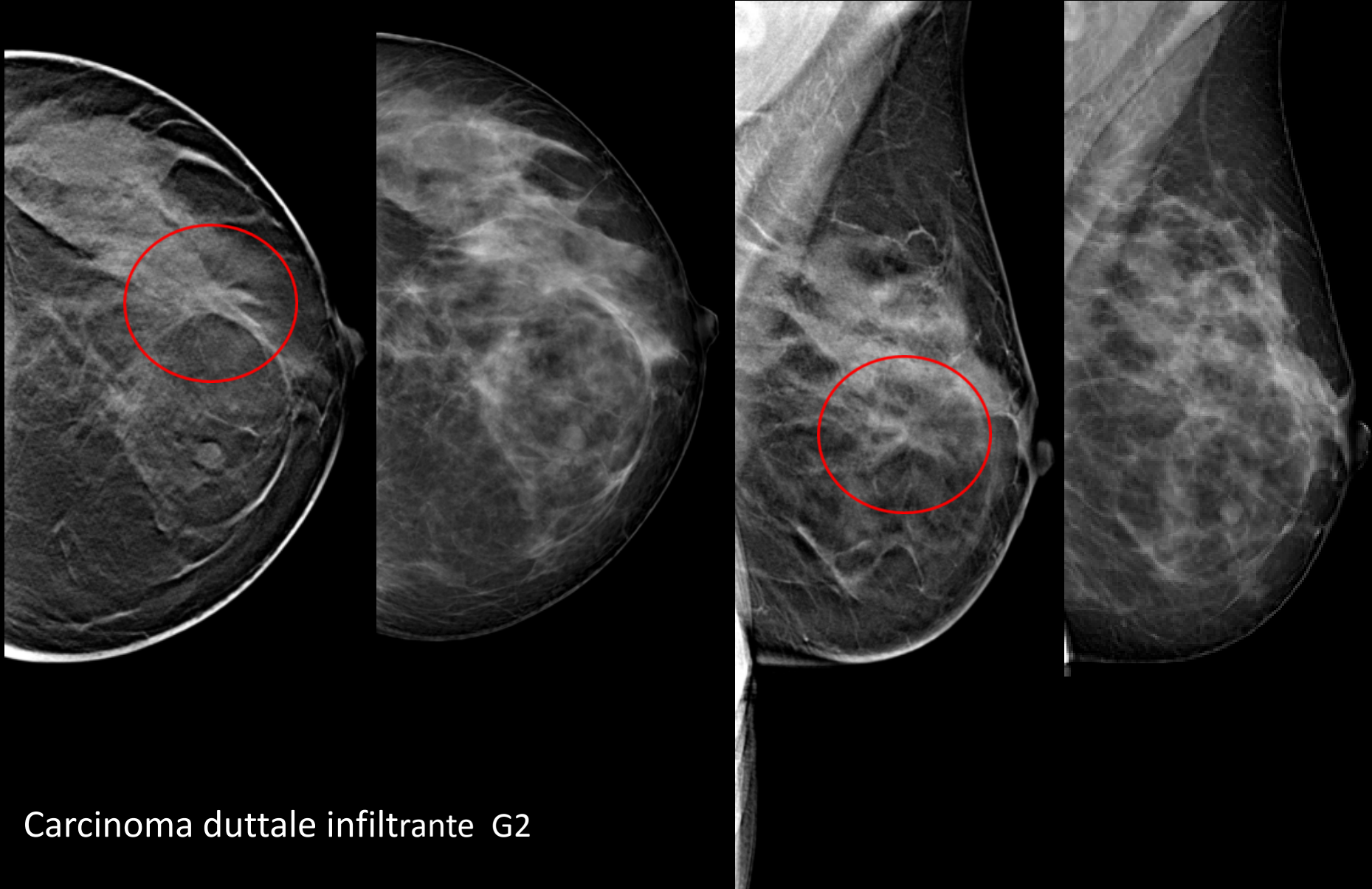
25 giugno 2014

CORSO PER
RADIOLOGI
Screening
mammografico:
il processo
e i problemi

Casistica sulla tomosintesi

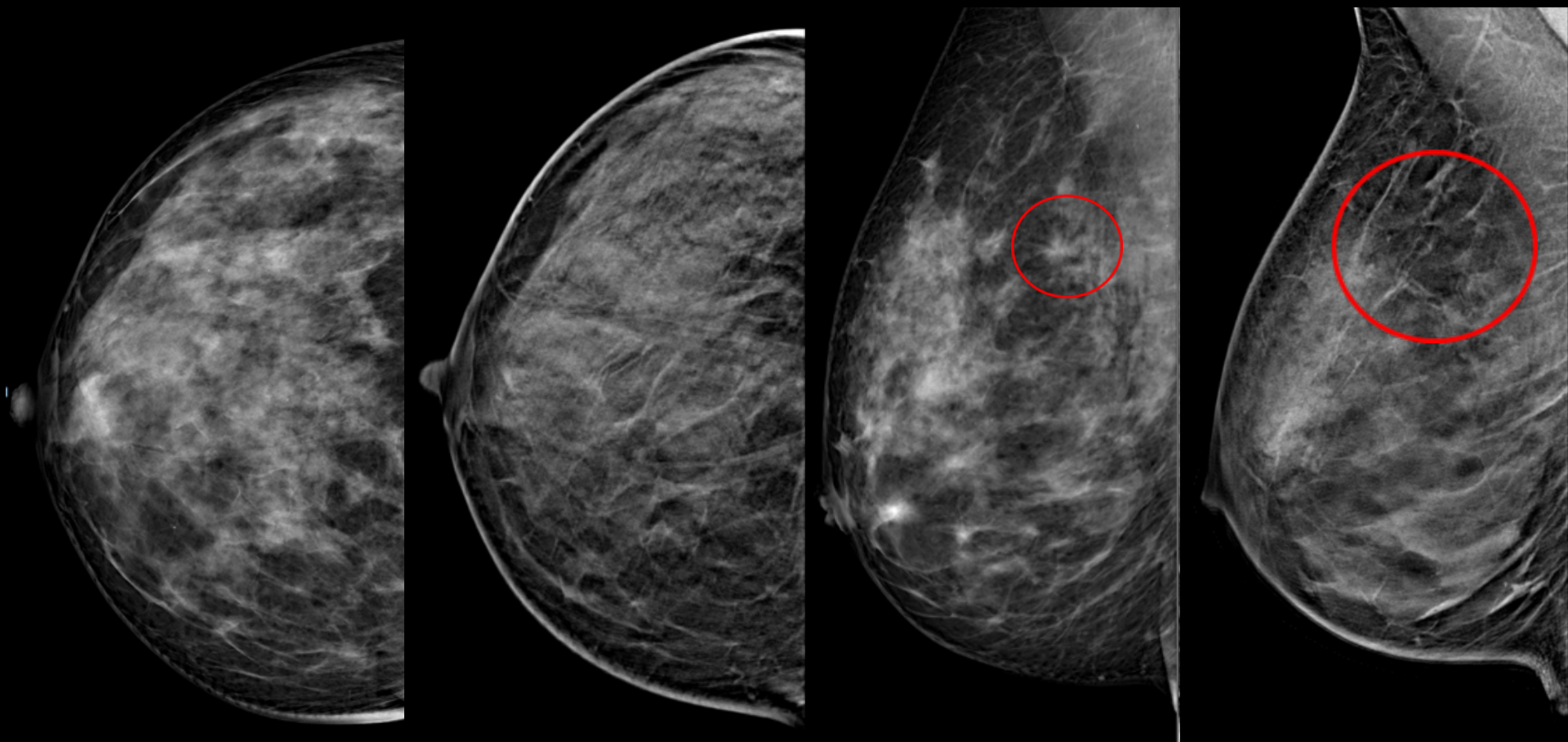
Alfredo Tafà
Osp. Bellaria
Bologna

48 anni, asintomatica, screening



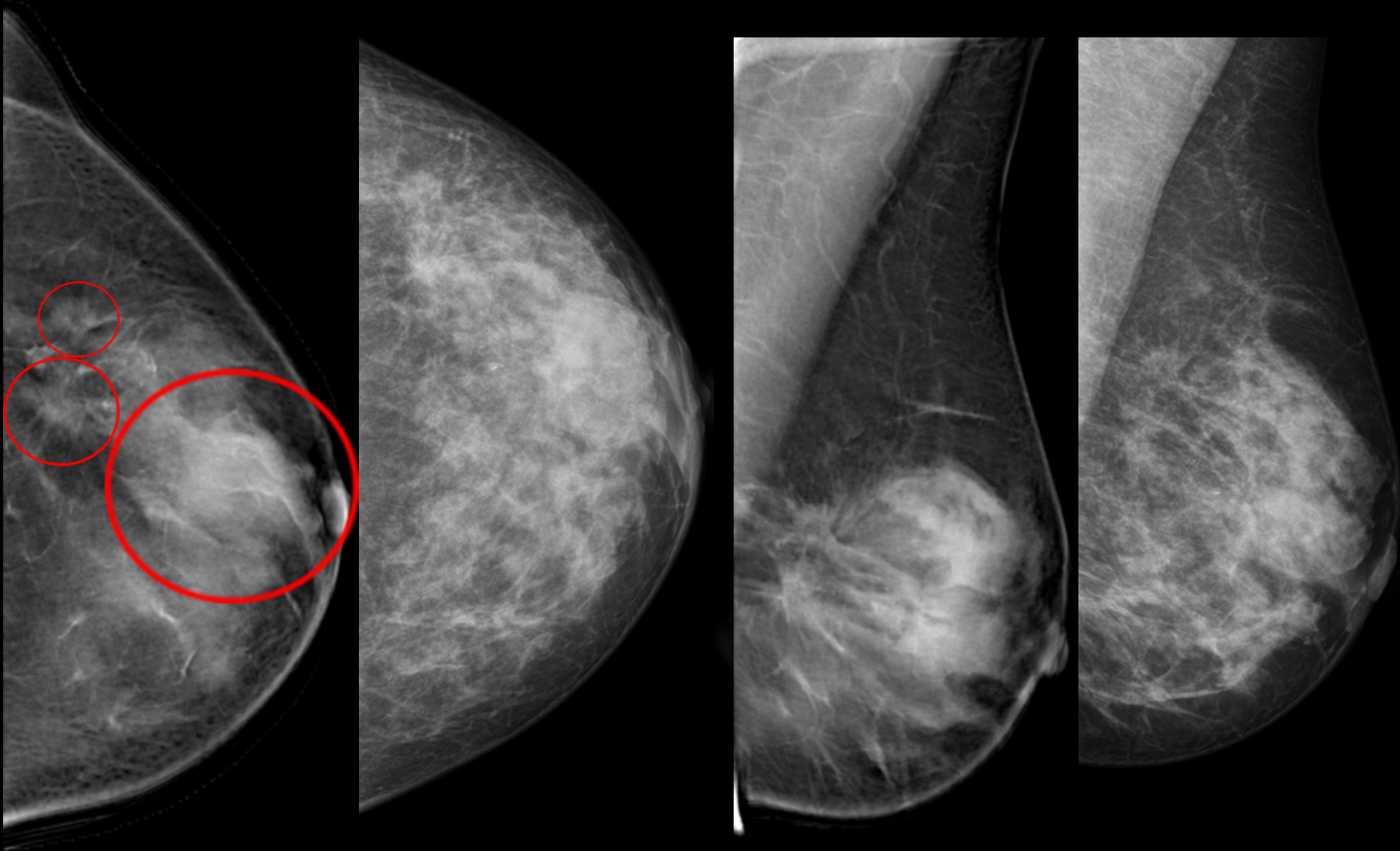
Carcinoma duttale infiltrante G2

52 anni, asintomatica, screening



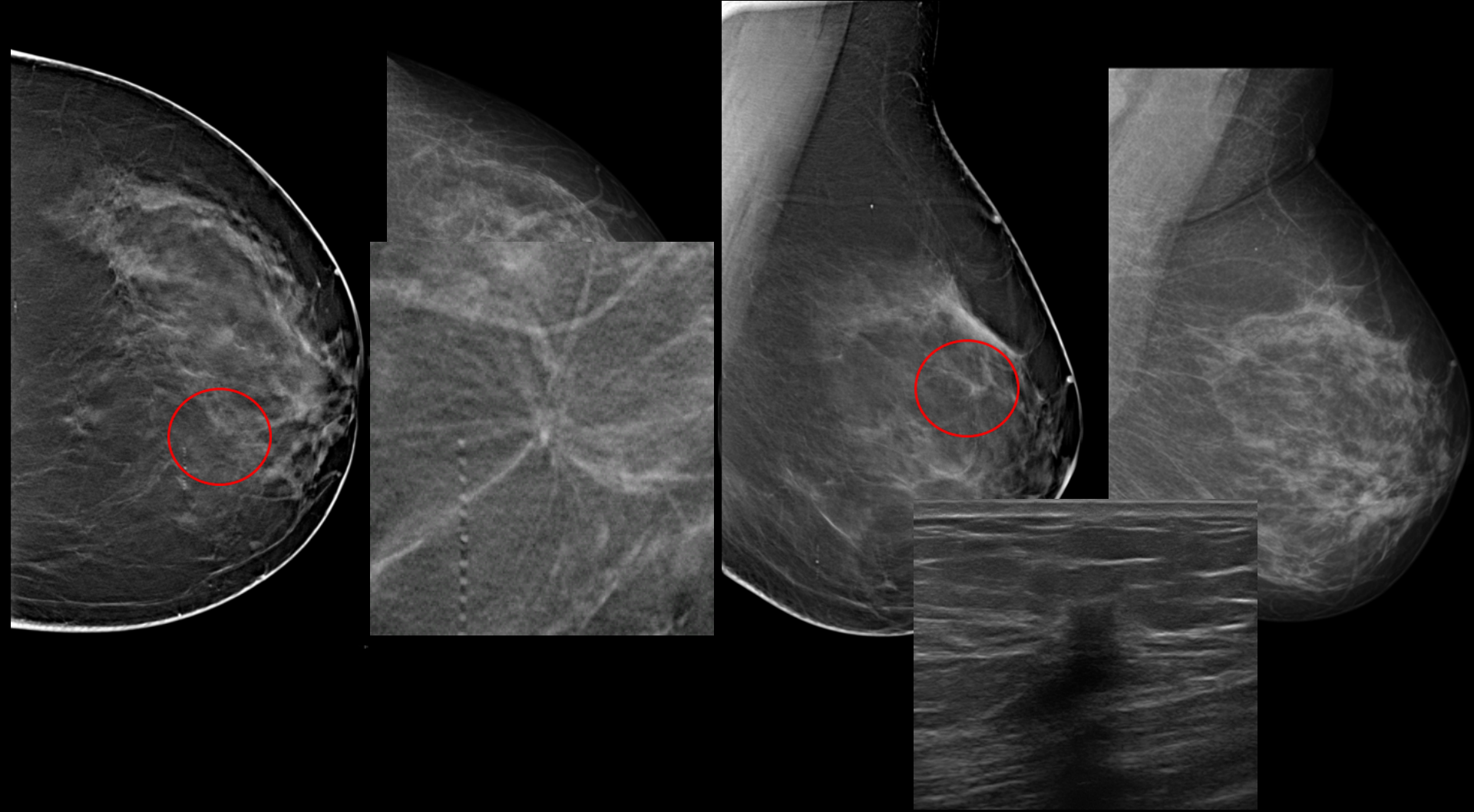
Secondo livello: tomosintesi ed ecografia negative

48 anni, reperto palpabile in sede supero-esterna sinistra, screening



Carcinoma duttale infiltrante G2

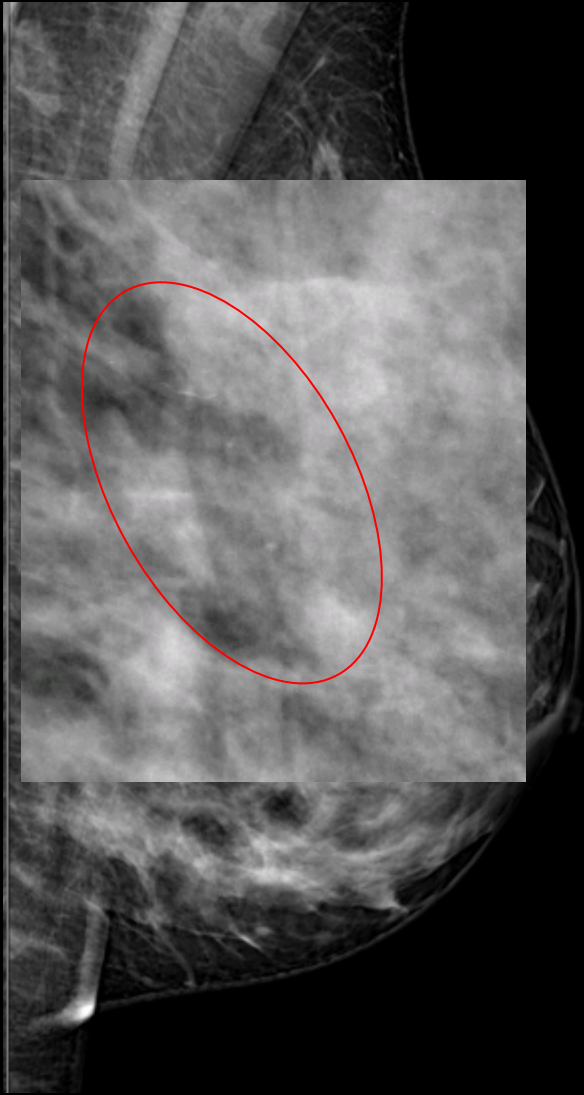
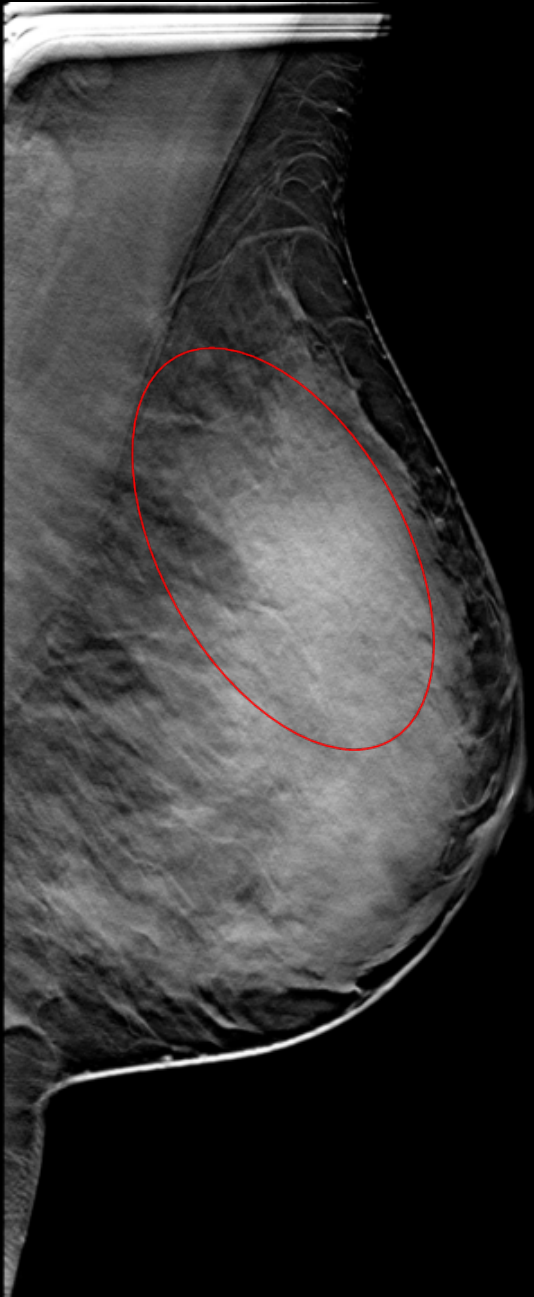

52 anni, asintomatica, screening



La Paziente rifiuta ulteriore approfondimento diagnostico

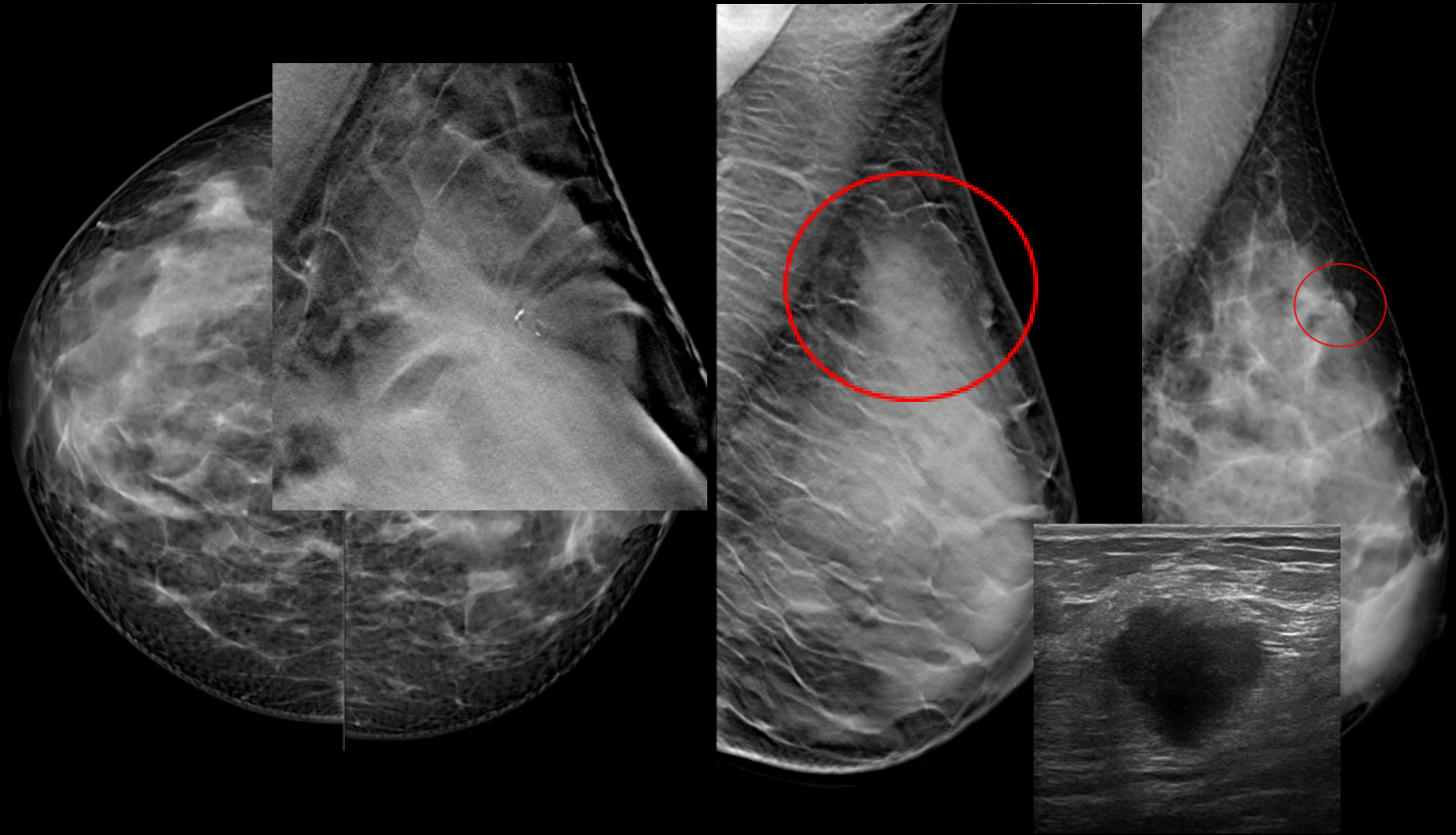


45 anni, asintomatica, screening



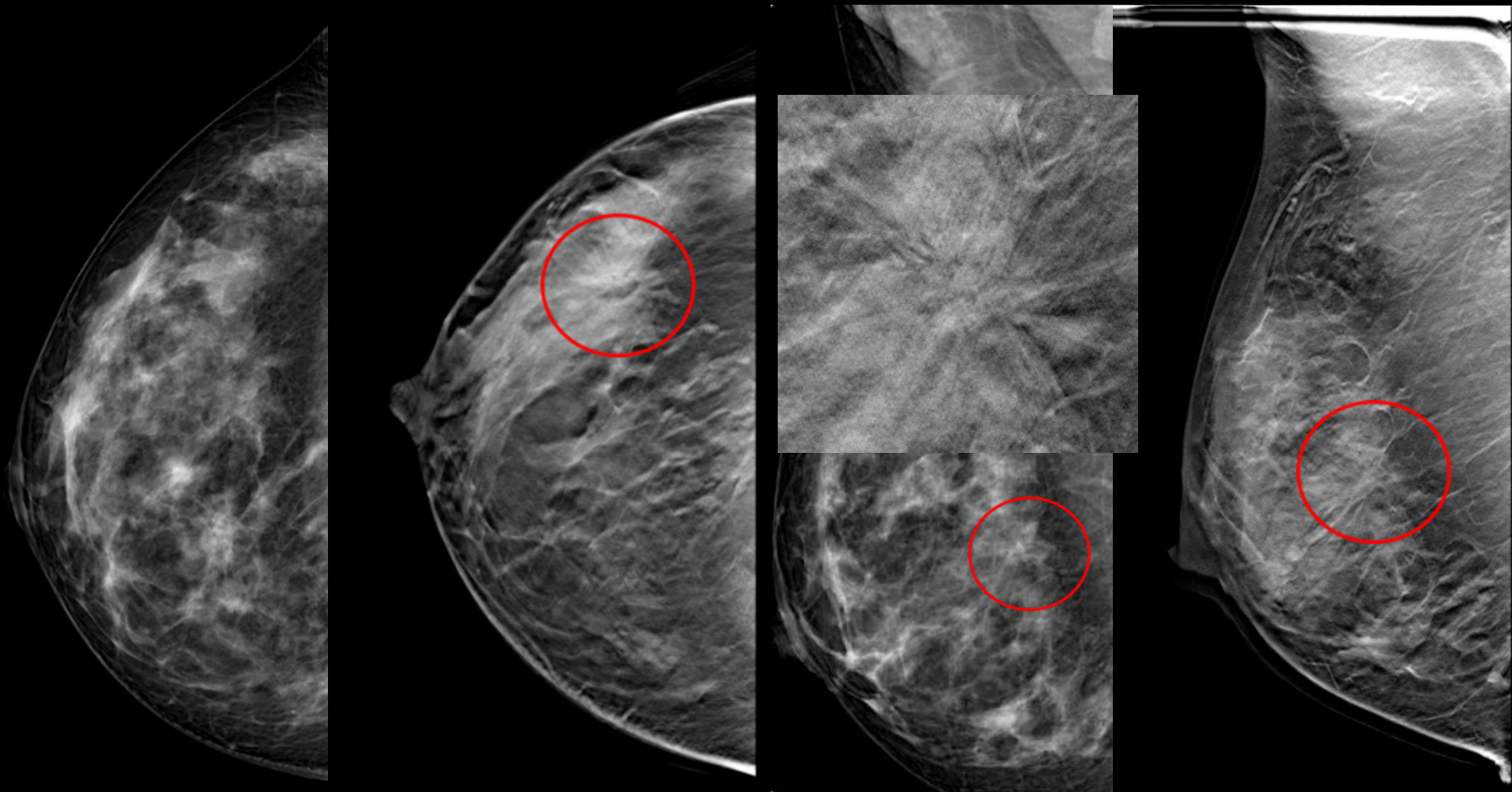
DCIS G2

43 anni, reperto palpabile in sede supero-esterna sinistra



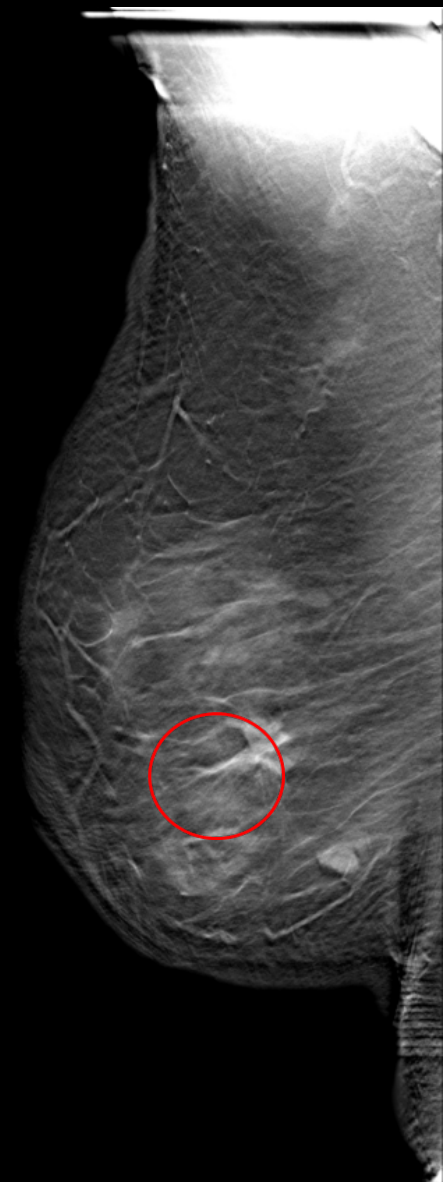
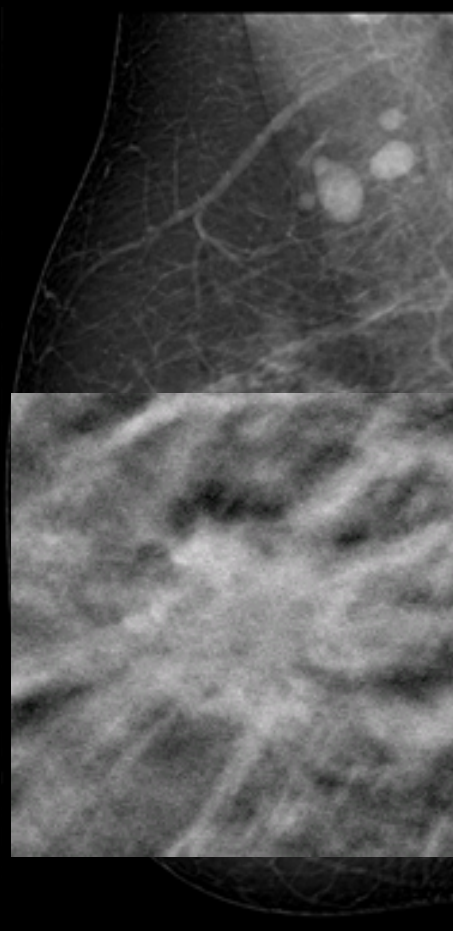
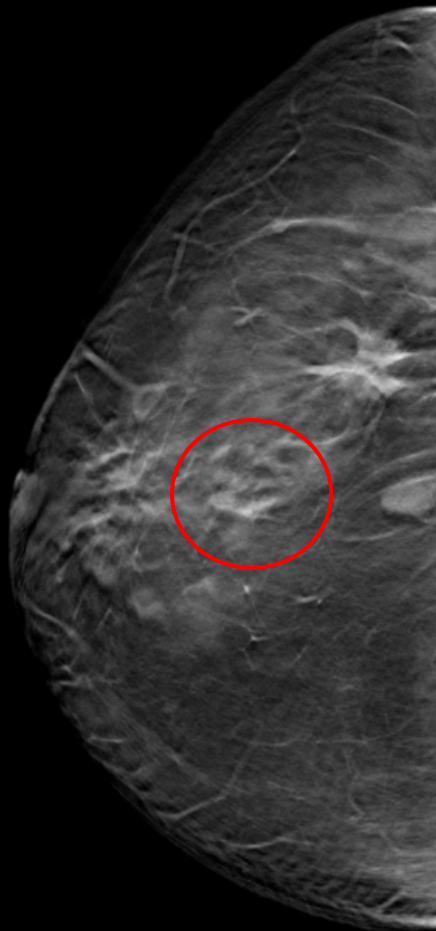
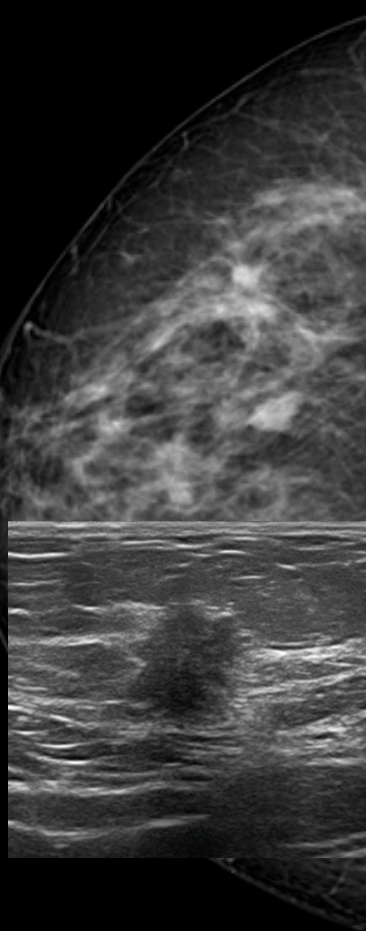
DIN 2 [G2 pT2 pN0(i+)sn]

45 anni, prima mammografia di screening, familiarità



Radial scar

54 anni, mastectomia sinistra, reperto palpabile in sede infero-esterna destra



Carcinoma duttale infiltrante G2



grazie